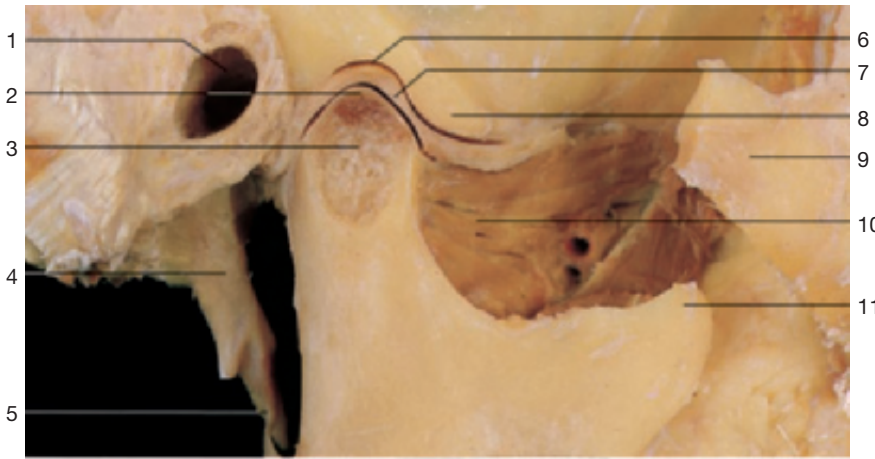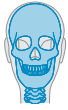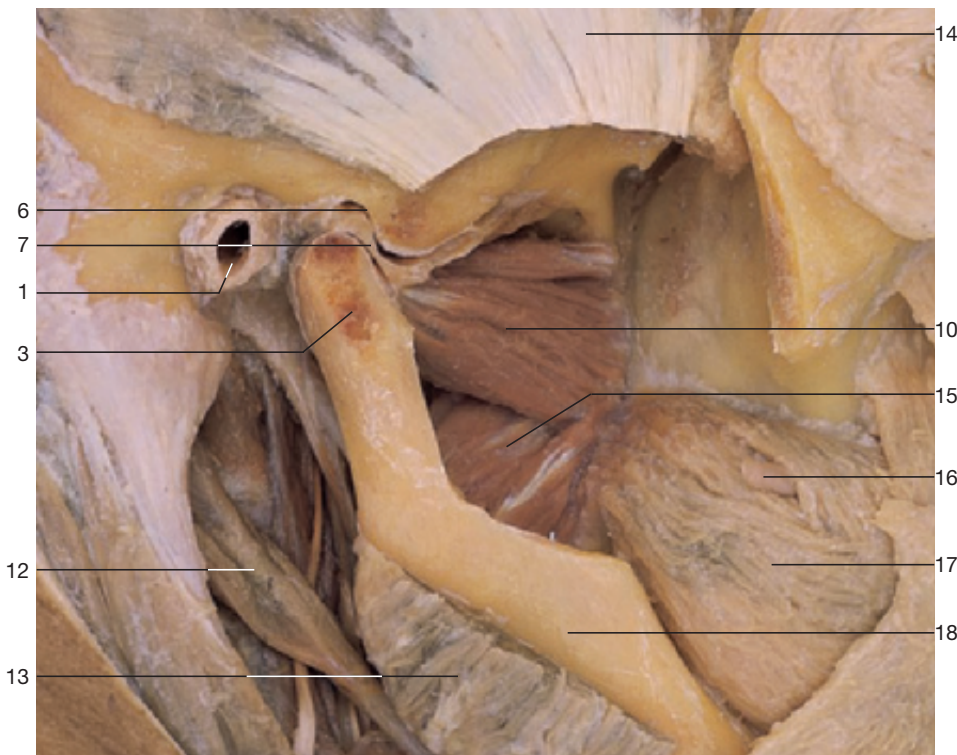
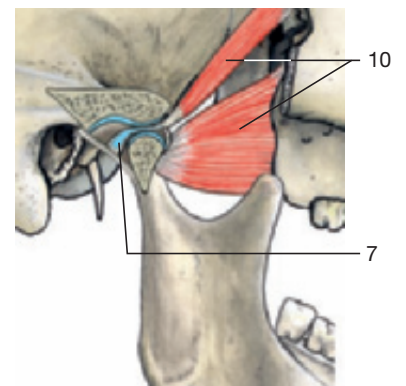
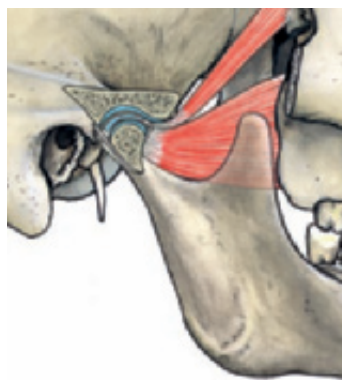
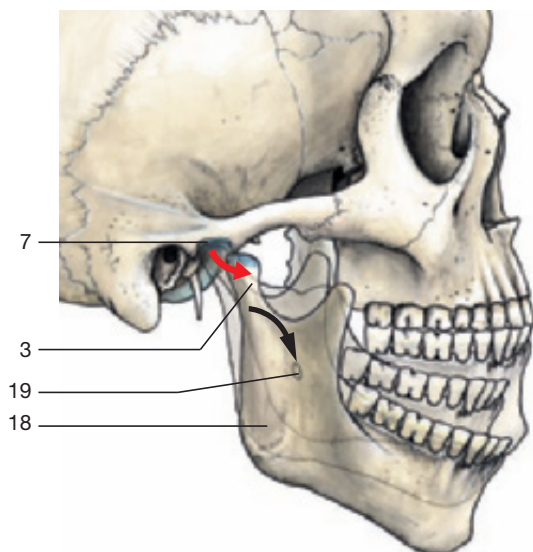


- 1 External acoustic meatus
- 2 Articular cartilage of condylar process
- 3 Condylar process of mandible
- 4 Styloid process
- 5 Stylomandibular ligament
- 6 Mandibular fossa
- 7 Articular disc
- 8 Articular tubercle
- 9 Zygomatic bone
- 10 Lateral pterygoid muscle
- 11 Coronoid process of mandible

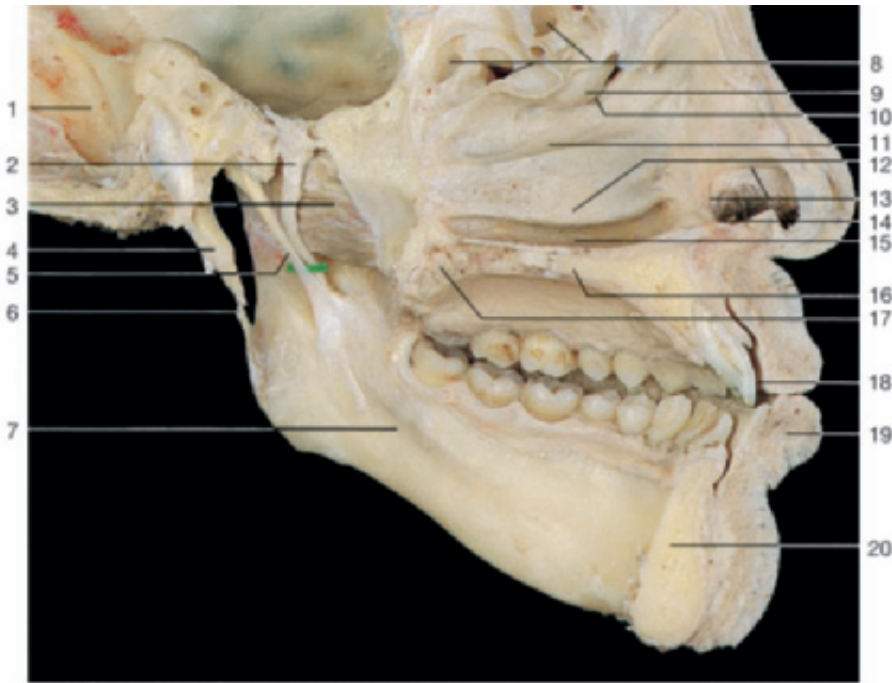
Temporomandibular joint (sagittal section).



Temporomandibular joint. Dissection of the articular disc and the related muscles (lateral aspect).

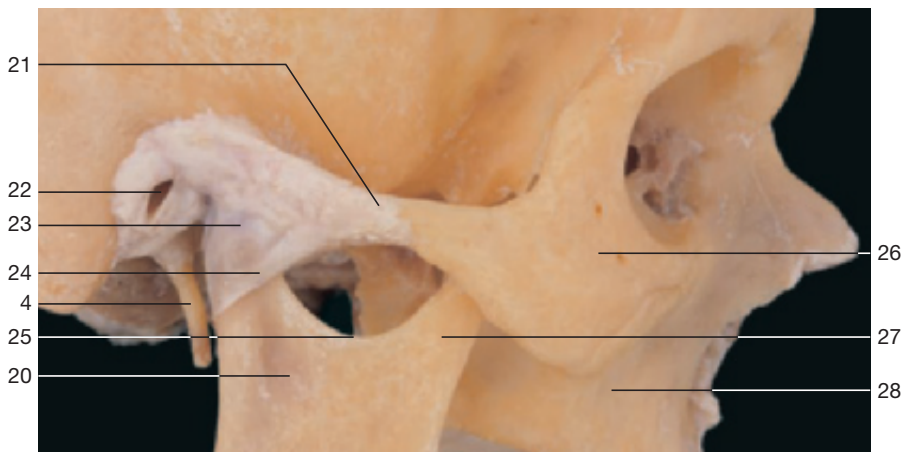


Movements of the temporomandibular joint and the related lateral pterygoid muscles.

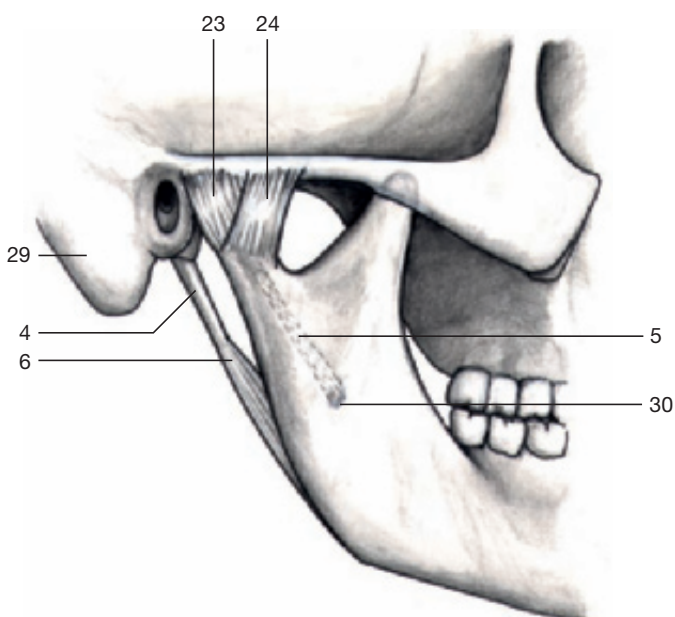


- 1 Groove for sigmoid sinus
- 2 Mandibular nerve
- 3 Lateral pterygoid muscle
- 4 Styloid process
- 5 Sphenomandibular ligament
- 6 Stylomandibular ligament
- 7 Mylohyoid groove
- 8 Ethmoidal air cells
- 9 Ethmoidal bulla
- 10 Hiatus semilunaris
- 11 Middle meatus
- 12 Inferior nasal concha
- 13 Limen nasi
- 14 Vestibule with hairs
- 15 Inferior meatus
- 16 Hard palate
- 17 Soft palate
- 18 Vestibule of oral cavity
- 19 Lower lip
- 20 Mandible
- 21 Zygomatic arch
- 22 External acoustic meatus
- 23 Articular capsule
- 24 Lateral ligament
- 25 Mandibular notch
- 26 Zygomatic bone
- 27 Coronoid process
- 28 Maxilla
- 29 Mastoid process
- 30 Mandibular foramen

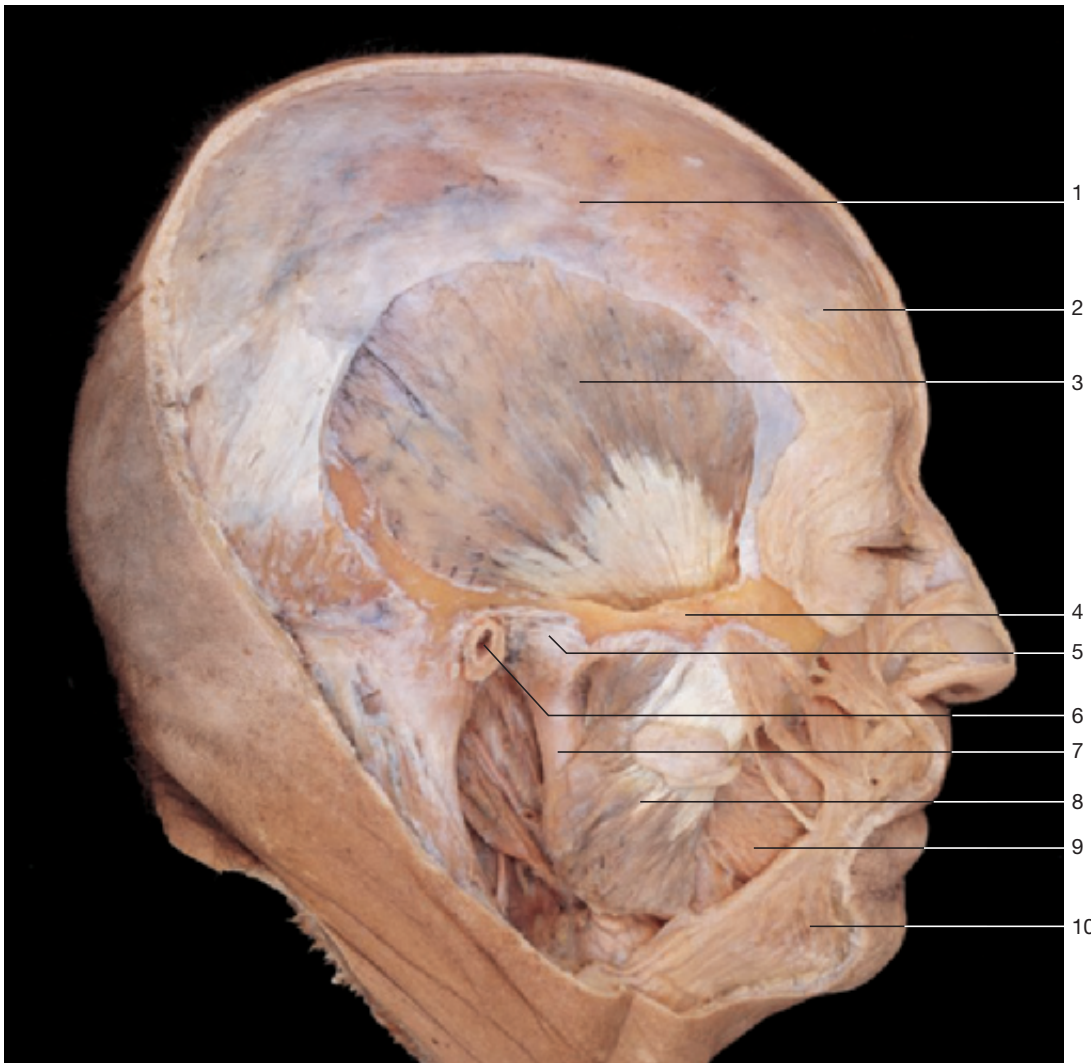
Ligaments of temporomandibular joint. Left half of the head (medial aspect).



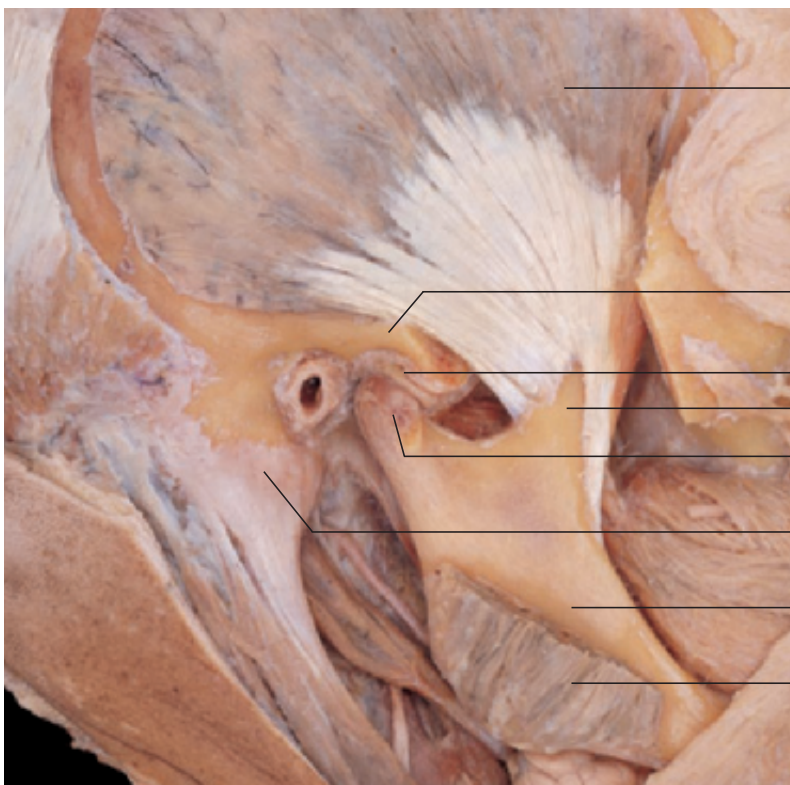
Temporomandibular joint with ligaments (lateral aspect).



Ligaments of temporomandibular joint (lateral aspect).

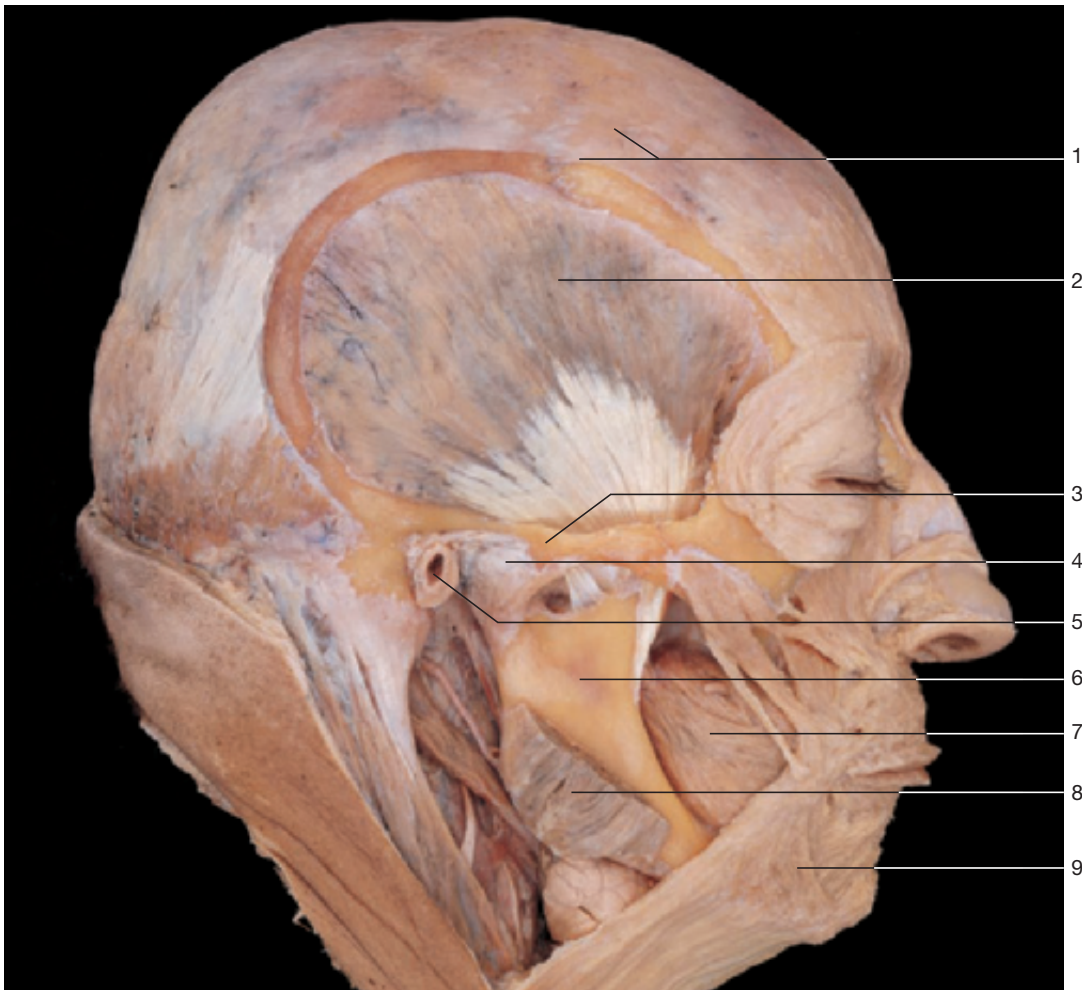

Temporomandibular joint and masticatory muscles. The masseter and temporal muscles are shown.

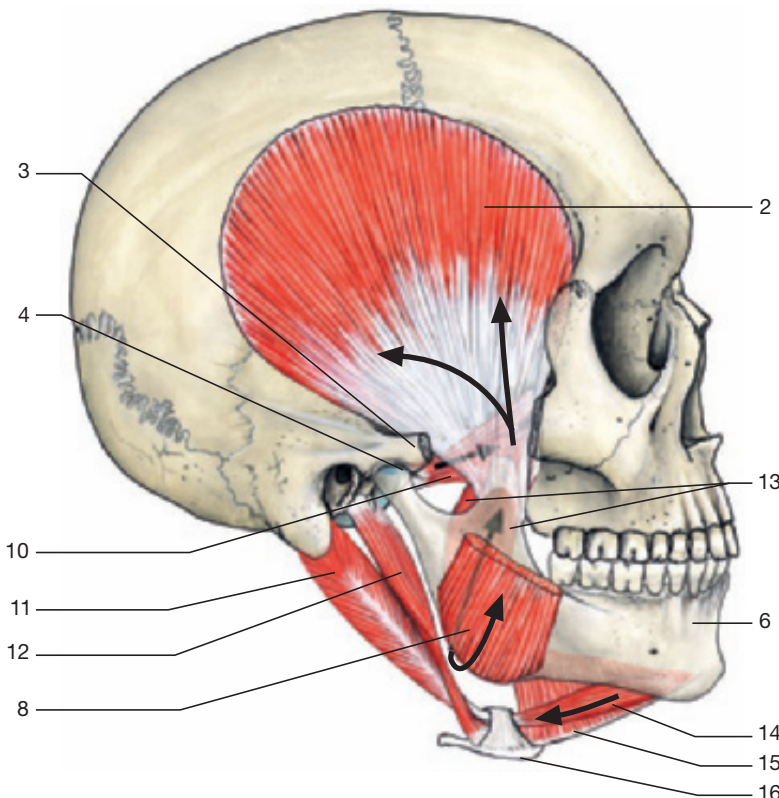


- 1 Galea aponeurotica
- 2 Frontal belly of occipitofrontalis muscle
- 3 Temporal muscle
- 4 Zygomatic arch
- 5 Temporomandibular joint
- 6 External acoustic meatus
- 7 Mandible
- 8 Masseter muscle
- 9 Buccinator muscle
- 10 Platysma muscle
- 11 Articular disc of temporomandibular joint
- 12 Coronoid process of mandible
- 13 Condylar process of mandible
- 14 Mastoid process

Temporal muscle with insertion at the mandible and the temporomandibular joint. Zygomatic arch and masseter muscle have been partly removed.

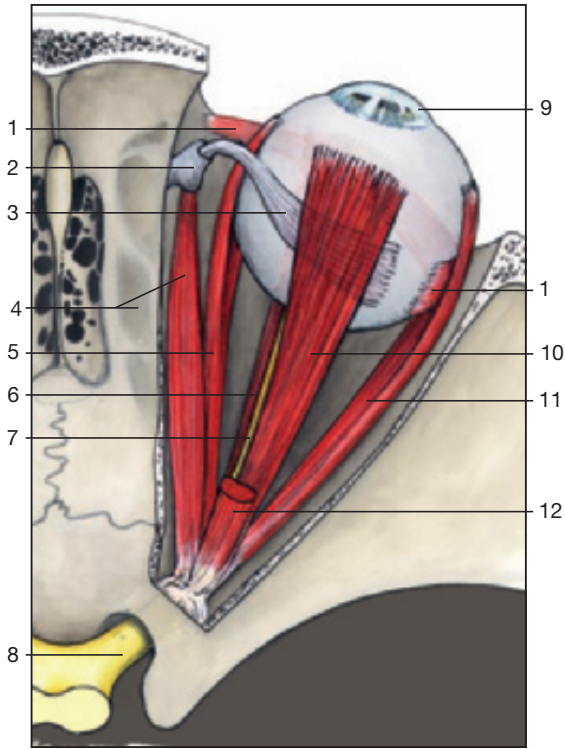
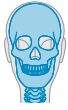

Temporomandibular joint and masticatory muscles. The masseter muscle has been partly removed.

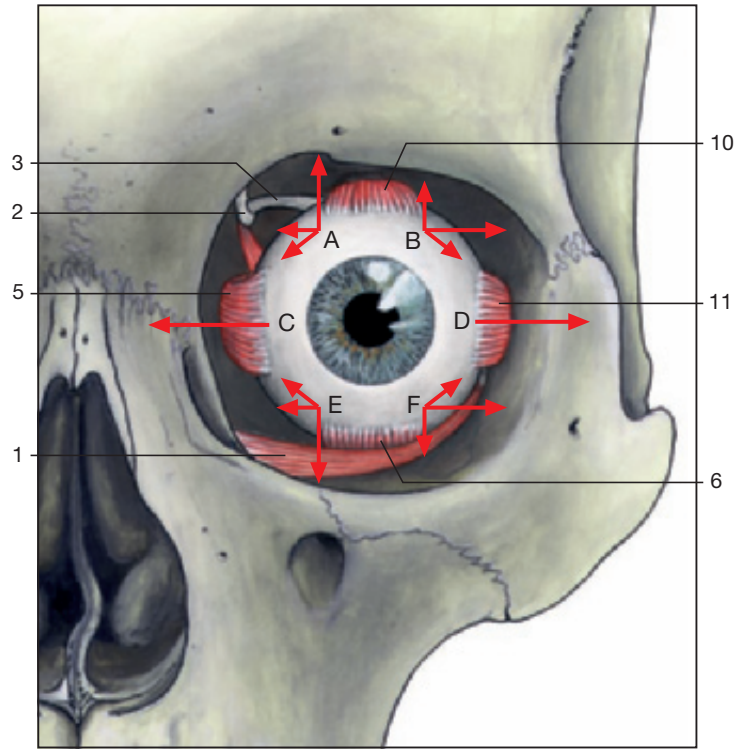


- 1 Galea aponeurotica
- 2 Temporal muscle
- 3 Zygomatic arch
- 4 Temporomandibular joint
- 5 External acoustic meatus
- 6 Mandible
- 7 Buccinator muscle
- 8 Masseter muscle (cut)
- 9 Platysma muscle
- 10 Lateral pterygoid muscle
- 11 Posterior belly of digastric muscle
- 12 Stylohyoid muscle
- 13 Medial pterygoid muscle
- 14 Anterior belly of digastric muscle
- 15 Mylohyoid muscle
- 16 Hyoid bone

Effect of the masticatory muscles on the temporomandibular joint (arrows).

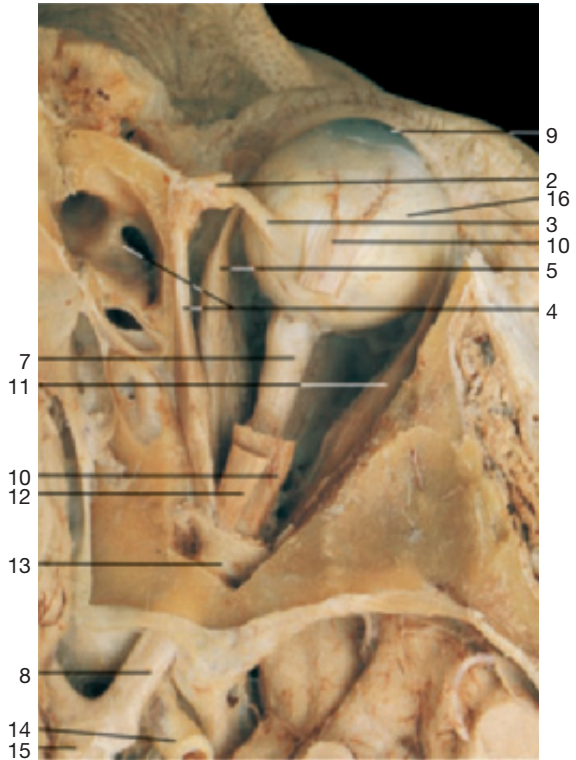

Right orbit with eyeball and extra-ocular muscles (from above). Levator palpebrae superioris muscle has been severed.

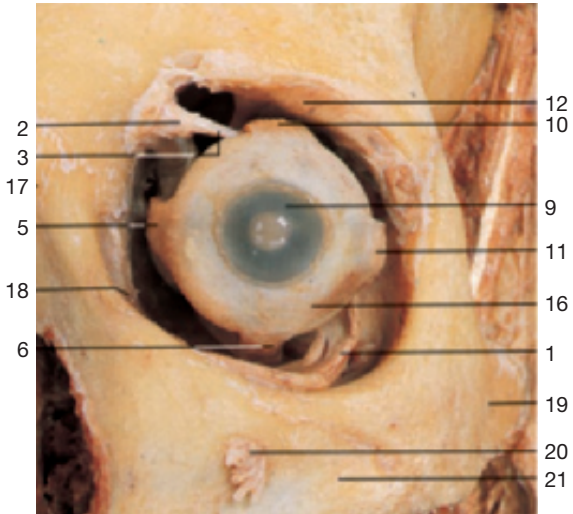

Action of the extra-ocular muscles (anterior aspect).

- | | |
|-----------------------------|-----------------------------|
| A = Superior rectus muscle | D = Lateral rectus muscle |
| B = Inferior oblique muscle | E = Inferior rectus muscle |
| C = Medial rectus muscle | F = Superior oblique muscle |

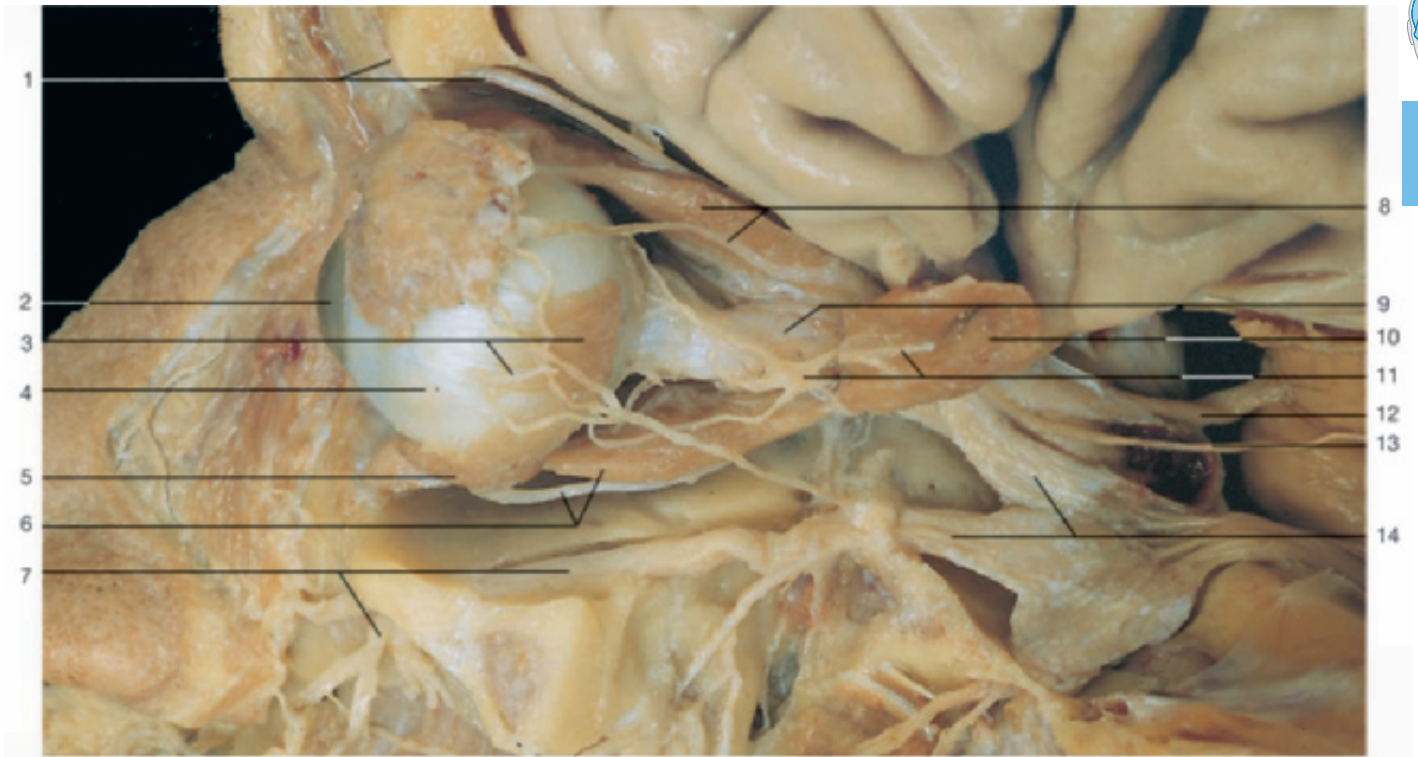


Right orbit with eyeball and extra-ocular muscles (from above). The roof of the orbit has been removed, the superior rectus muscle and the levator palpebrae superioris muscle have been severed.

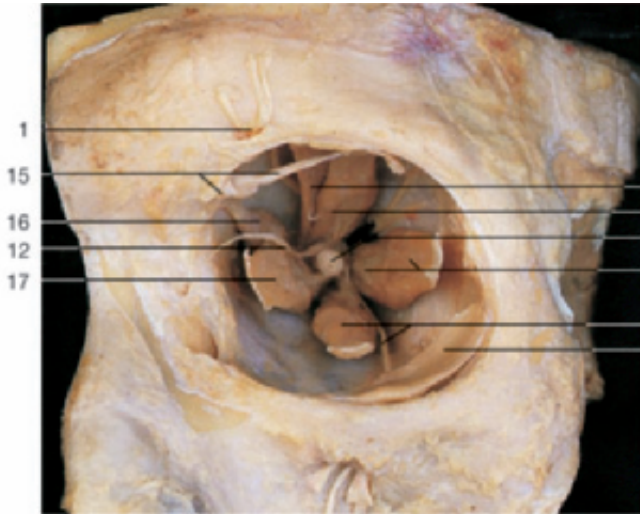


Left orbit with eyeball and extra-ocular muscles (anterior aspect). Lids, conjunctiva, and lacrimal apparatus have been removed.

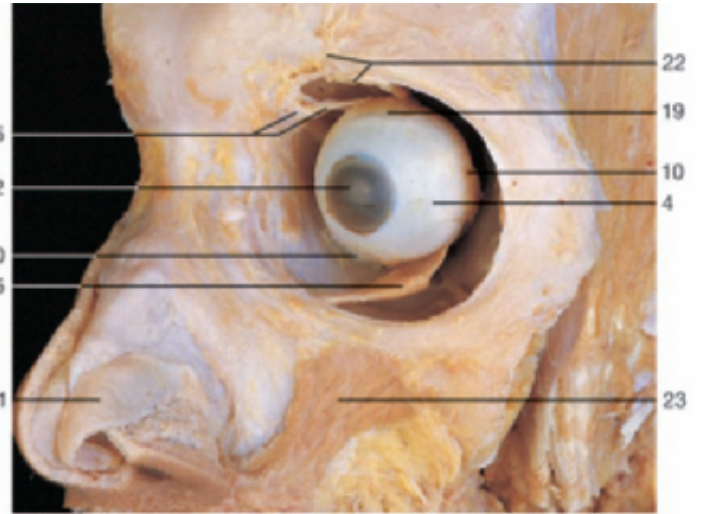
- | | |
|---|--|
| 1 Inferior oblique muscle | 12 Levator palpebrae superioris muscle |
| 2 Trochlea | 13 Common annular tendon |
| 3 Tendon of superior oblique muscle | 14 Internal carotid artery |
| 4 Superior oblique muscle and ethmoid air cells | 15 Optic chiasma |
| 5 Medial rectus muscle | 16 Sclera |
| 6 Inferior rectus muscle | 17 Nasal bone |
| 7 Optic nerve (extracranial part) | 18 Nasolacrimal duct |
| 8 Optic nerve (intracranial part) | 19 Zygomatic bone |
| 9 Cornea | 20 Infra-orbital nerves |
| 10 Superior rectus muscle | 21 Maxilla |
| 11 Lateral rectus muscle | |



Extra-ocular muscles and their nerves (lateral aspect of the left eye). Lateral rectus muscle divided and reflected.



Left orbit with extra-ocular muscles (anterior aspect). Eyeball removed.



Extra-ocular muscles (antero-lateral aspect).

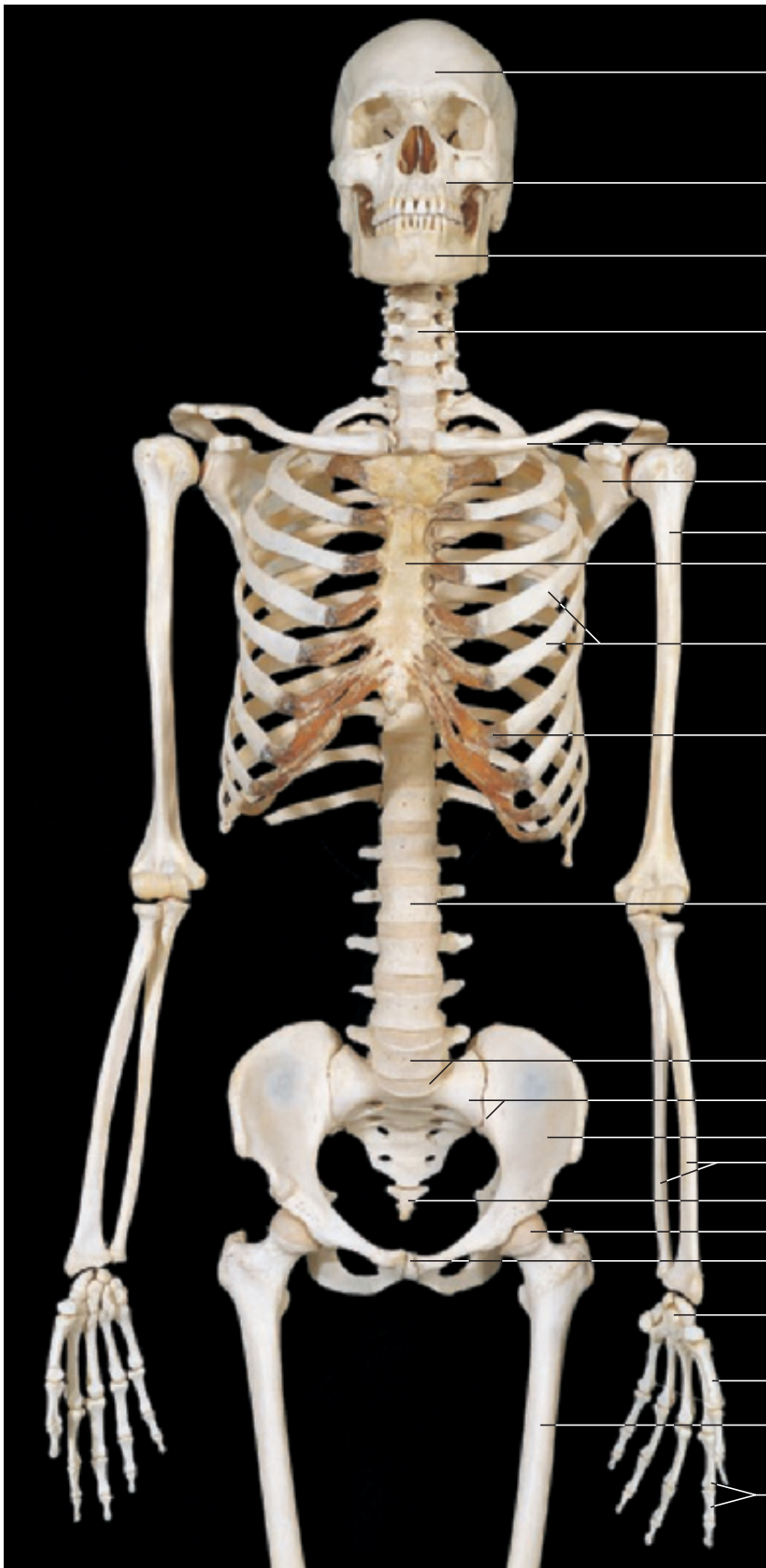
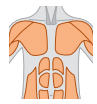
- 1 Supra-orbital nerve
- 2 Cornea
- 3 Insertion of lateral rectus muscle
- 4 Eyeball (sclera)
- 5 Inferior oblique muscle
- 6 Inferior rectus muscle and inferior branch of oculomotor nerve
- 7 Infra-orbital nerve
- 8 Superior rectus muscle and lacrimal nerve
- 9 Optic nerve (n. II)
- 10 Lateral rectus muscle
- 11 Ciliary ganglion and abducens nerve (n. VI)

- 12 Oculomotor nerve (n. III)
- 13 Trochlear nerve (n. IV)
- 14 Ophthalmic nerve (n. V₁) and maxillary nerve (n. V₂)
- 15 Trochlea and tendon of superior oblique muscle
- 16 Superior oblique muscle
- 17 Medial rectus muscle
- 18 Levator palpebrae superioris muscle
- 19 Superior rectus muscle
- 20 Inferior rectus muscle
- 21 Greater alar cartilage
- 22 Supra-orbital nerve and levator palpebrae superioris muscle
- 23 Levator labii superioris muscle

3 Trunk

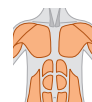Skeleton _____	190	Inguinal Region _____	221
Head and Vertebral Column _____	193	Surface Anatomy of the Back _____	225
Vertebrae _____	198	Back _____	226
Thorax and Vertebral Column _____	201	Spinal Cord _____	234
Ligaments of the Vertebral Column _____	206	Lumbar Part of the Vertebral Column and Spinal Cord _____	238
Surface Anatomy of the Anterior Body _____	208	Vertebral Canal and Spinal Cord _____	240
Thoracic Wall _____	210	Nuchal Region _____	242
Thoracic and Abdominal Walls _____	212		



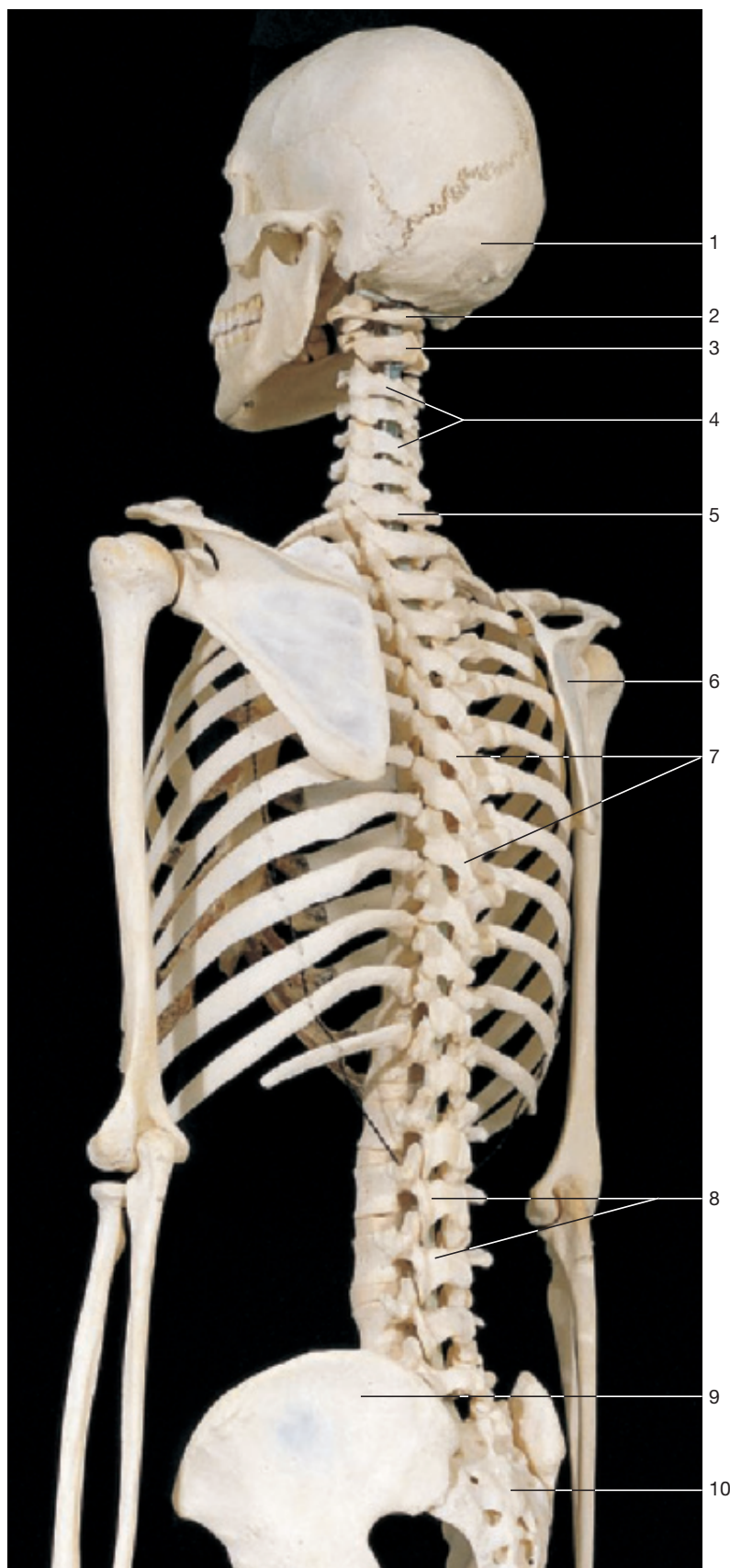


- 1 Frontal bone
- 2 Maxilla
- 3 Mandible
- 4 Cervical vertebrae
- 5 Clavicle
- 6 Scapula
- 7 Humerus
- 8 Sternum
- 9 Ribs
- 10 Costal cartilage
- 11 Lumbar vertebrae
- 12 Lumbar vertebra (L₅) and promontory
- 13 Sacrum
- 14 Hip bone
- 15 Radius and ulna
- 16 Coccyx
- 17 Head of femur
- 18 Pubic symphysis
- 19 Carpal bones
- 20 Metacarpal bones
- 21 Femur
- 22 Phalanges

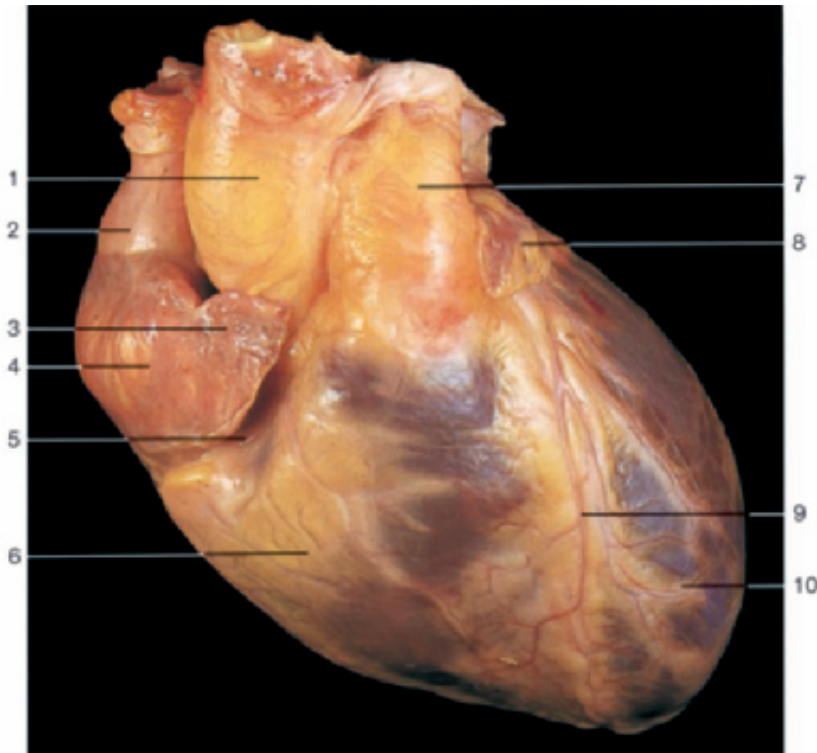
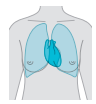
Skeleton of the trunk with head, vertebral column, thorax, pelvis, and upper limb (anterior aspect).



- 1 Occipital bone
- 2 Atlas
- 3 Axis
- 4 Cervical vertebrae
- 5 Vertebra prominens (C₇)
- 6 Scapula
- 7 Thoracic vertebrae
- 8 Lumbar vertebrae
- 9 Hip bone
- 10 Sacrum

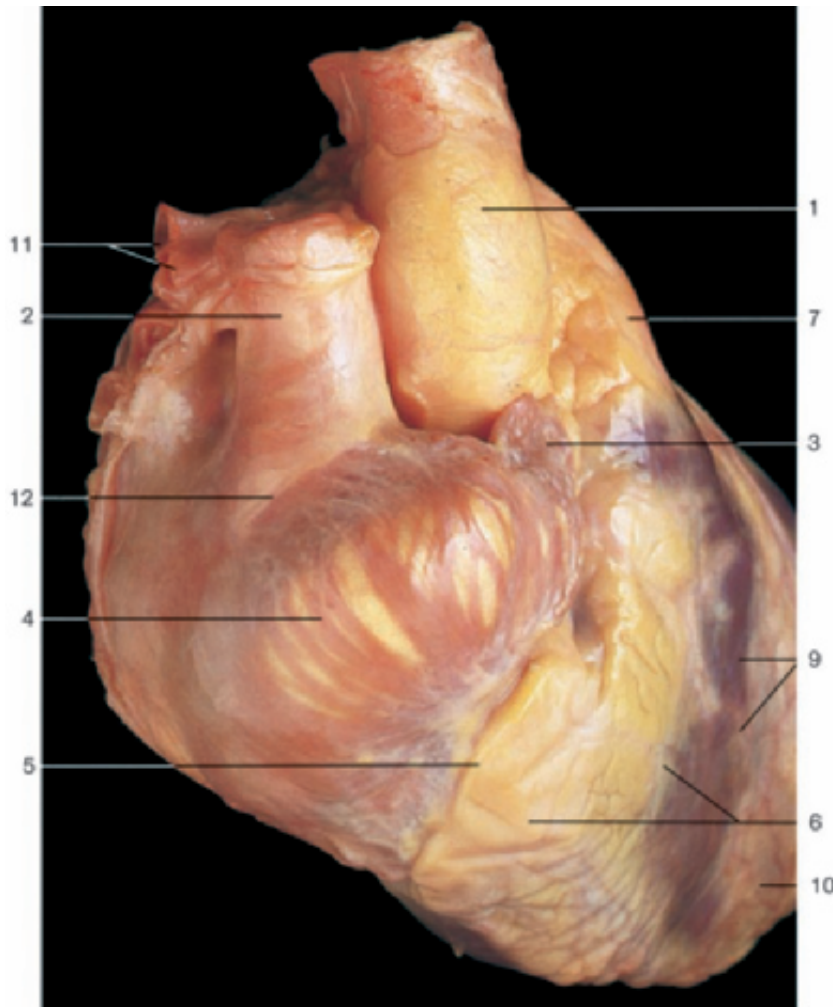


Skeleton of the trunk with head, vertebral column, thorax, pelvis, and shoulder girdle (oblique-posterior aspect).

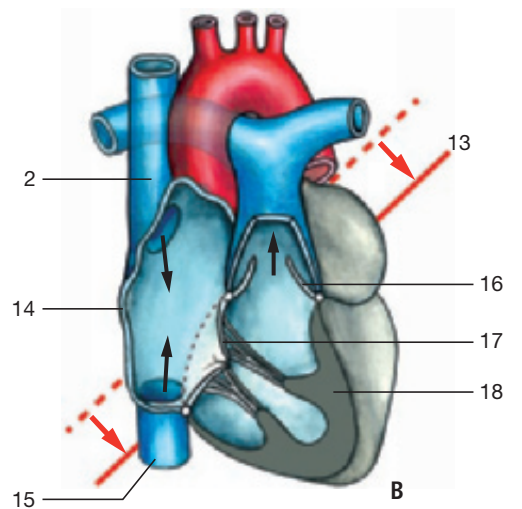
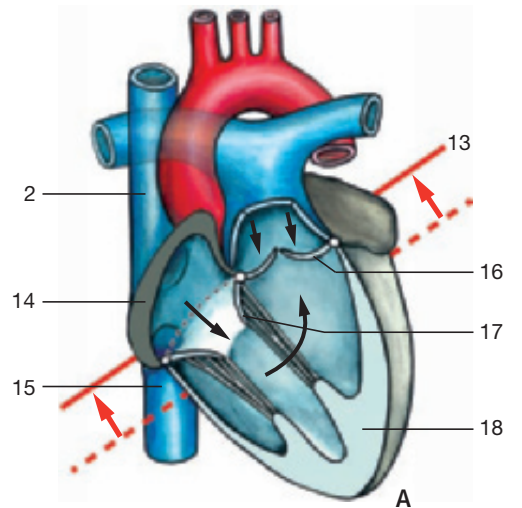


Heart, fixed in diastole (anterior aspect). The ventricles are relaxed, atria contracted.

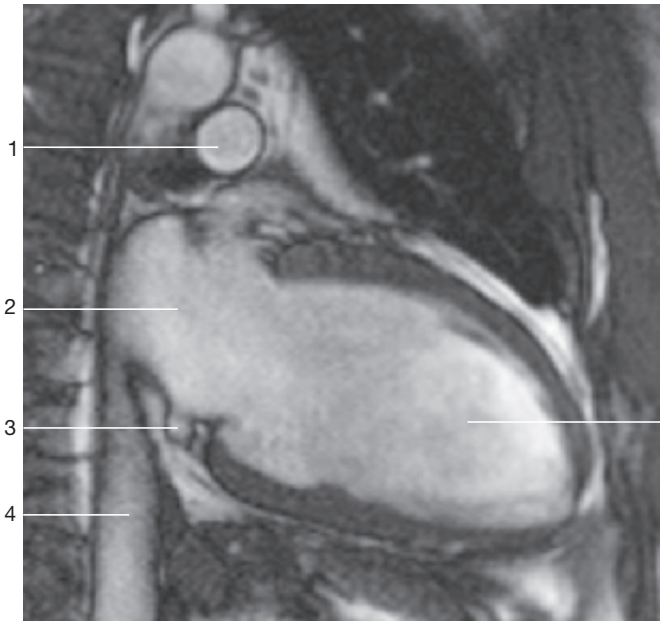
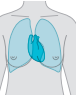- 1 Ascending aorta
- 2 Superior vena cava
- 3 Right auricle
- 4 Right atrium
- 5 Coronary sulcus
- 6 Right ventricle
- 7 Pulmonary trunk
- 8 Left auricle
- 9 Anterior interventricular sulcus
- 10 Left ventricle
- 11 Right pulmonary artery
- 12 Sulcus terminalis with sinu-atrial node
- 13 Line indicating plane of position of valves
- 14 Myocardium of right atrium
- 15 Inferior vena cava
- 16 Valve of pulmonary trunk
- 17 Right tricuspid valve
- 18 Myocardium of right ventricle



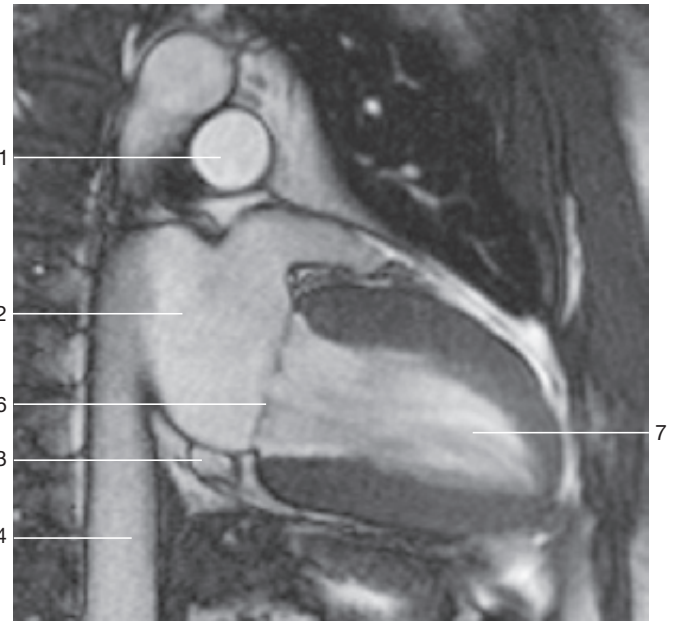
Heart, fixed in systole (antero-lateral aspect). The ventricles are contracted, atria dilated.



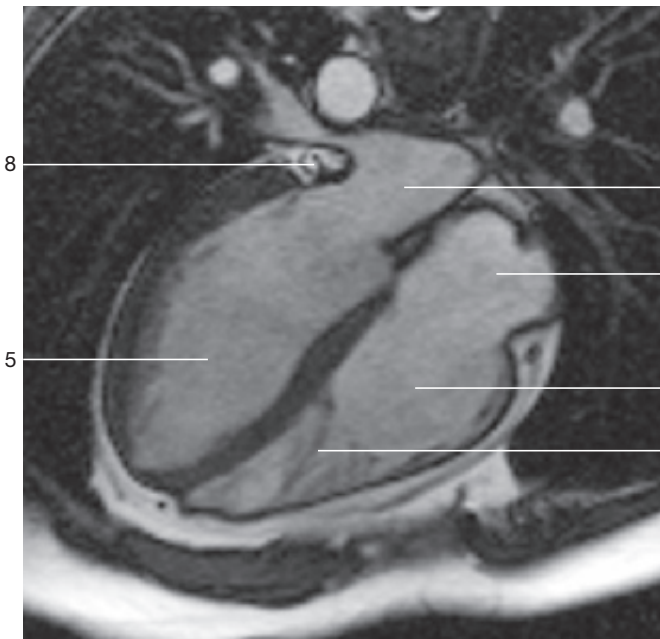
Morphological changes during heart movements. Note the changes in position of the valves (red arrows). Contracted portions of heart are indicated in dark gray. A = **Diastole**: muscles of the ventricles relaxed, atrioventricular valves open, semilunar valves closed. B = **Systole**: muscles of ventricles contracted, atrioventricular valves closed, semilunar valves open.



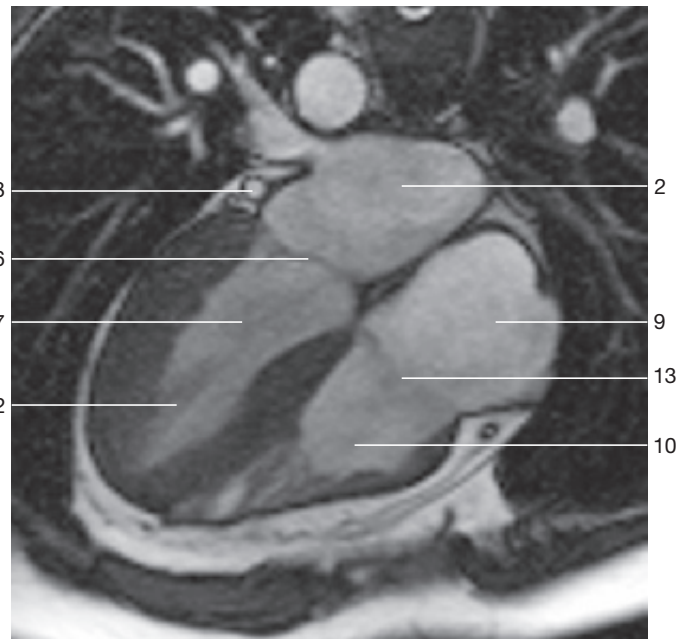
Coronal section through the thorax at the level of the left ventricle in dilation (MRI scan). (Prof. Uder, Dept. of Radiology, Univ. Erlangen-Nuremberg, Germany.)



Coronal section through the thorax at the level of the left ventricle in contraction (MRI scan). (Prof. Uder, Dept. of Radiology, Univ. Erlangen-Nuremberg, Germany.)



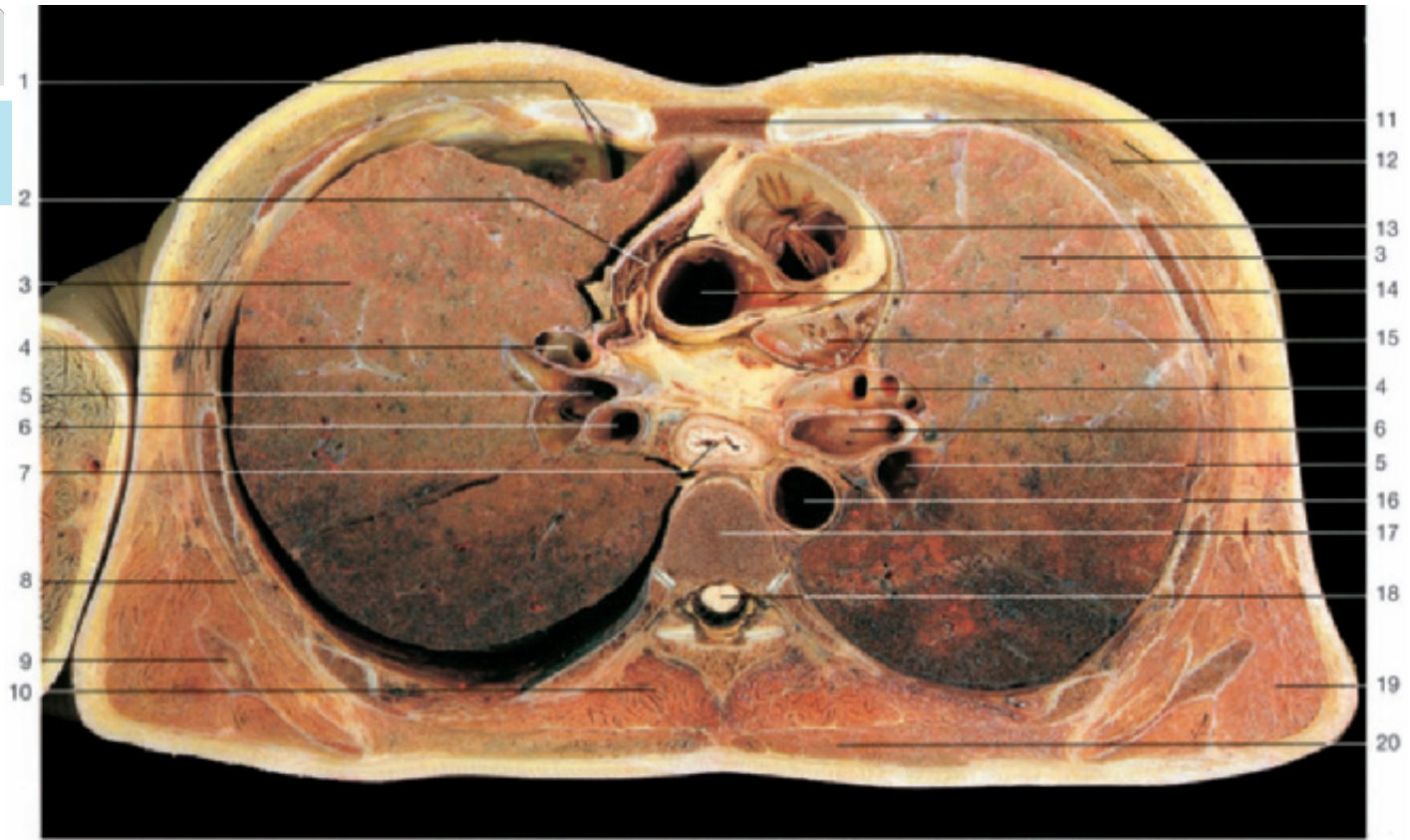
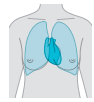
Coronal section through the human heart in the process of dilation (MRI scan). (Prof. Uder, Dept. of Radiology, Univ. Erlangen-Nuremberg, Germany.)



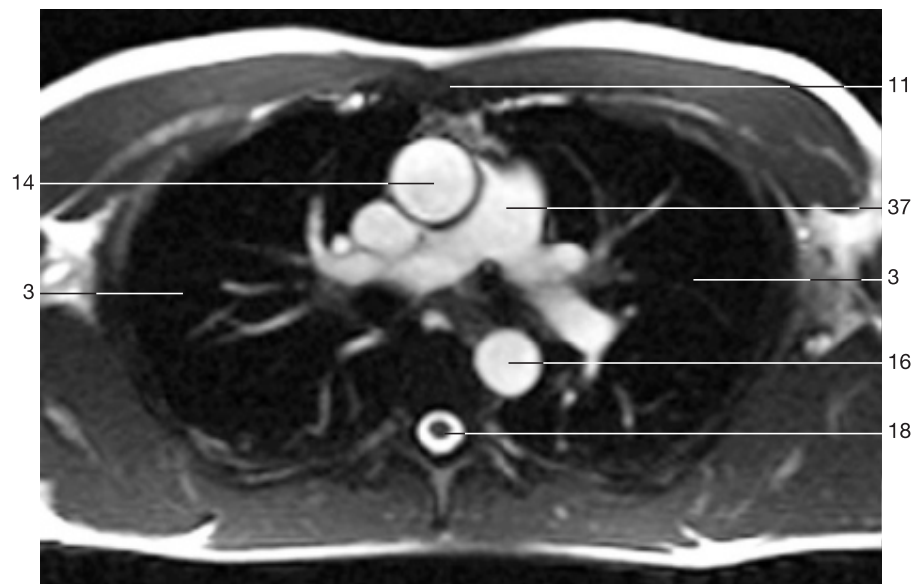
Coronal section through the human heart in the process of contraction (MRI scan). (Prof. Uder, Dept. of Radiology, Univ. Erlangen-Nuremberg, Germany.)

- 1 Pulmonary artery
- 2 Left atrium
- 3 Coronary sinus
- 4 Inferior vena cava
- 5 Left ventricle (dilated)
- 6 Left atrioventricular (mitral) valve
- 7 Left ventricle (contracted)

- 8 Great cardiac vein (left coronary vein)
- 9 Right atrium
- 10 Right ventricle
- 11 Septomarginal trabecula
- 12 Papillary muscle
- 13 Right atrioventricular (tricuspid) valve

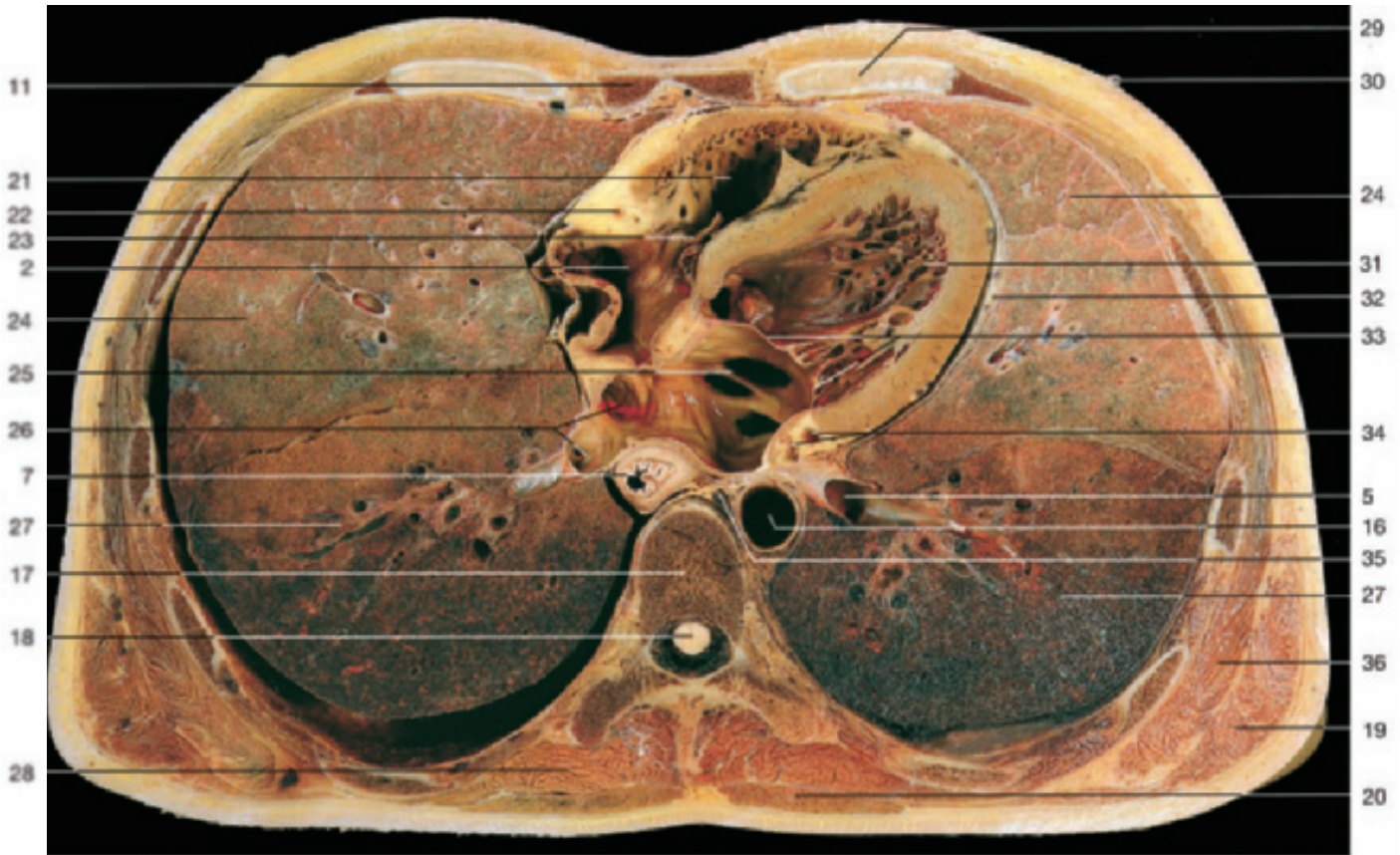

Horizontal section through the thorax. Section 1 (from below).

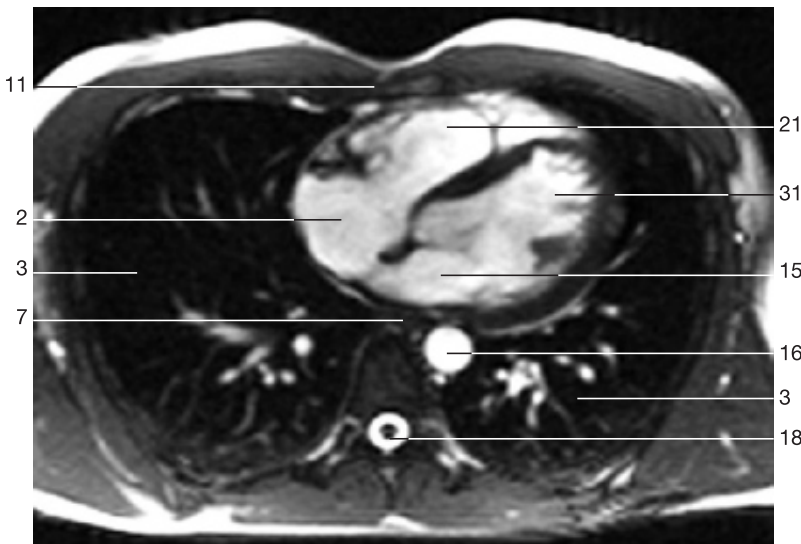


Horizontal section through the thorax at the level of section 1 (MRI scan).
(Prof. Bautz and Dr. Janka, Dept. of Radiology, Univ. Erlangen-Nuremberg, Germany.)

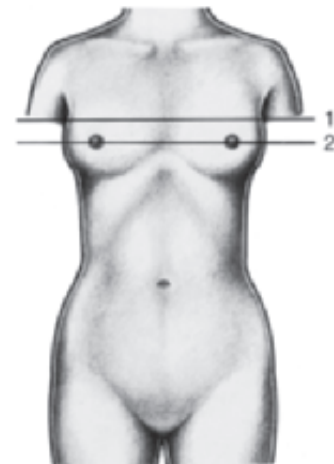
- | | |
|-------------------------------------|--|
| 1 Internal thoracic artery and vein | 12 Pectoralis major and minor muscles |
| 2 Right atrium | 13 Conus arteriosus (right ventricle) and pulmonic valve |
| 3 Lung | 14 Ascending aorta and left coronary artery (only in the upper figure) |
| 4 Pulmonary artery | 15 Left atrium |
| 5 Pulmonary vein | 16 Descending aorta |
| 6 Primary bronchus | 17 Thoracic vertebra |
| 7 Esophagus | 18 Spinal cord |
| 8 Serratus anterior muscle | 19 Latissimus dorsi muscle |
| 9 Scapula | 20 Trapezius muscle |
| 10 Longissimus thoracis muscle | |



Horizontal section through the thorax. Section 2 (from below).

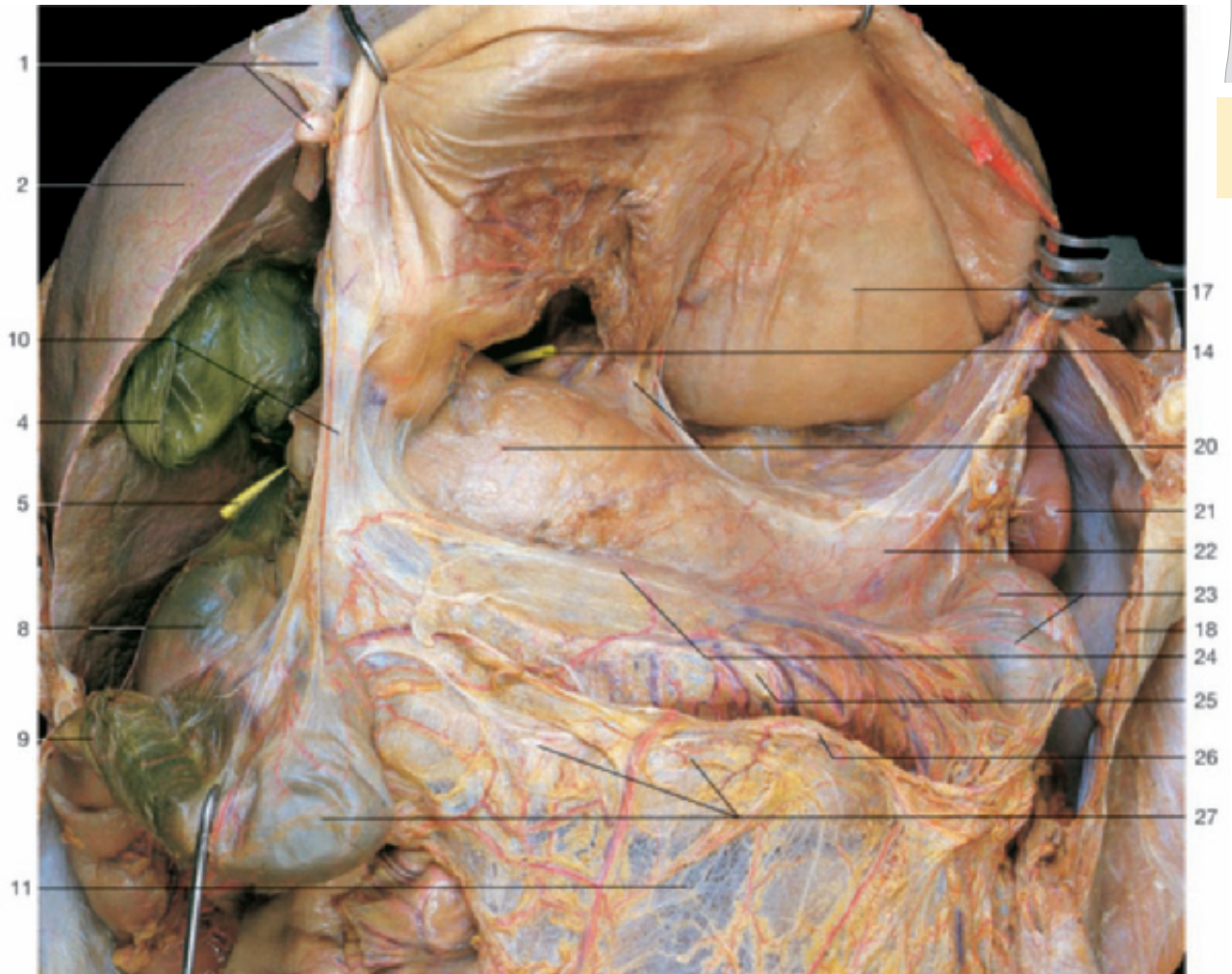
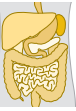

Horizontal section through the thorax at the level of section 2 (MRI scan).
(Prof. Bautz and Dr. Janka, Dept. of Radiology, Univ. Erlangen-Nuremberg, Germany.)

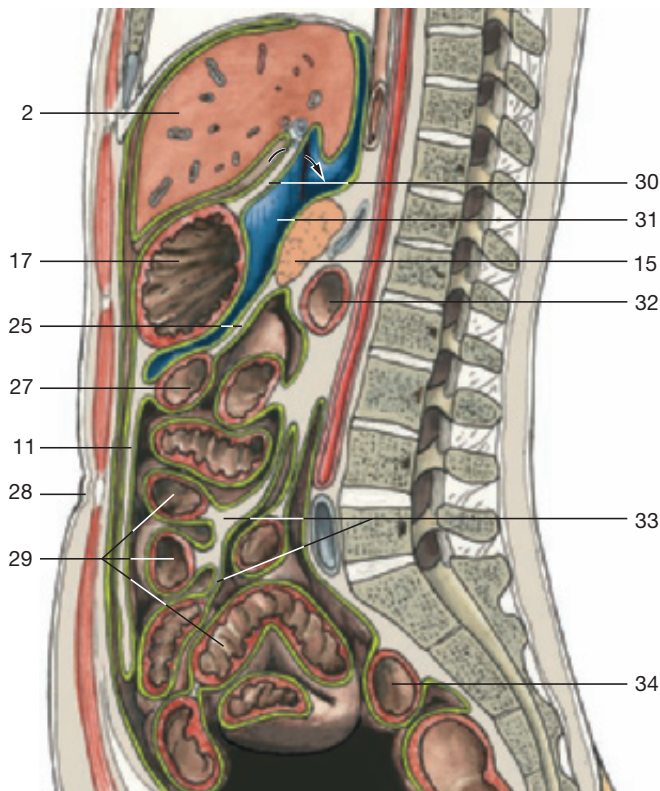


Horizontal section through the thorax.
Levels of the sections are indicated.

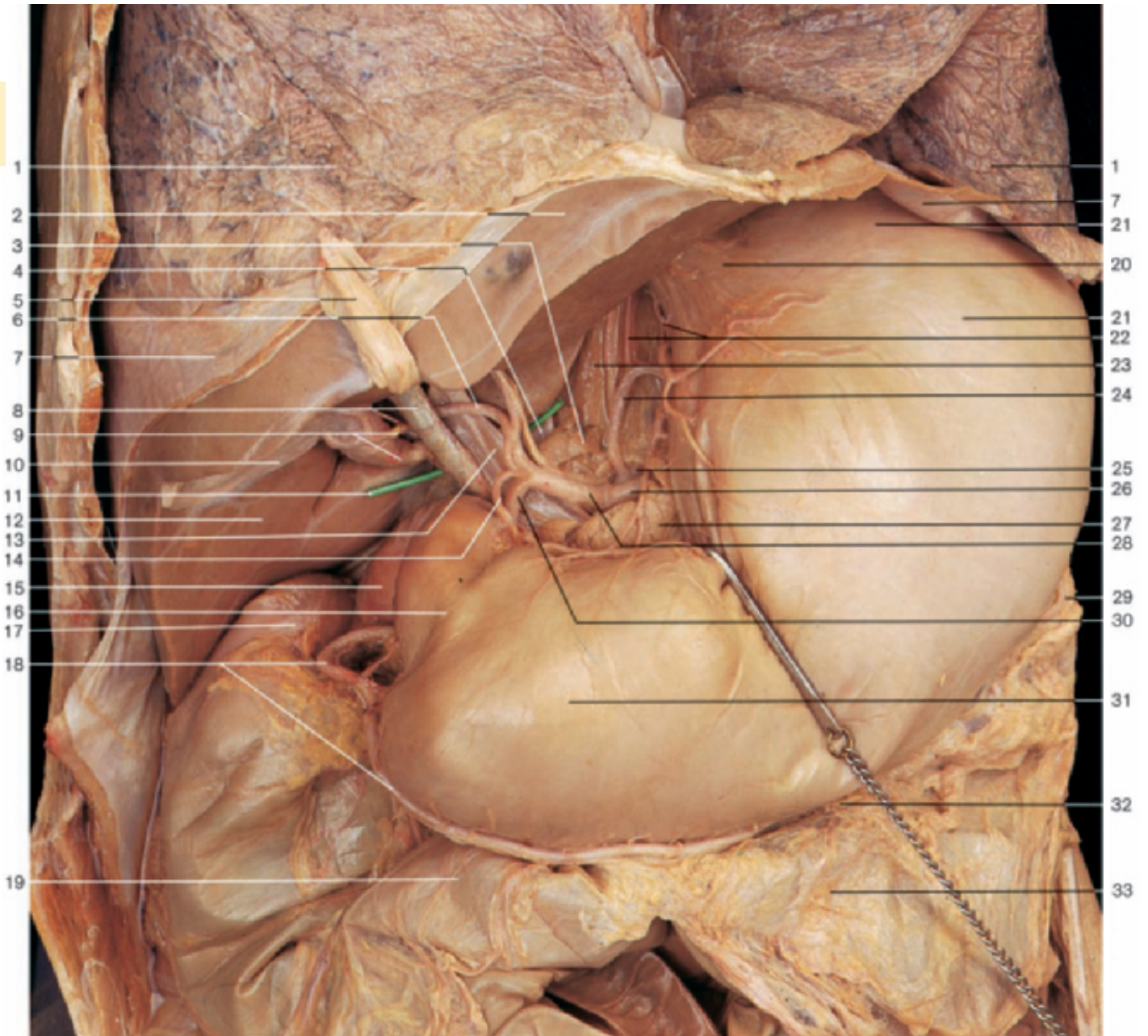
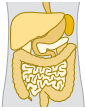- | | |
|---------------------------------|--|
| 21 Right ventricle | 30 Nipple |
| 22 Right coronary artery | 31 Left ventricle |
| 23 Right atrioventricular valve | 32 Pericardium |
| 24 Lung (upper lobe) | 33 Left atrioventricular valve |
| 25 Left atrium | 34 Left coronary artery and coronary sinus |
| 26 Pulmonary veins | 35 Accessory hemiazygos vein |
| 27 Lung (lower lobe) | 36 Serratus anterior muscle |
| 28 Erector muscle of spine | 37 Pulmonary trunk |
| 29 Third costal cartilage | |



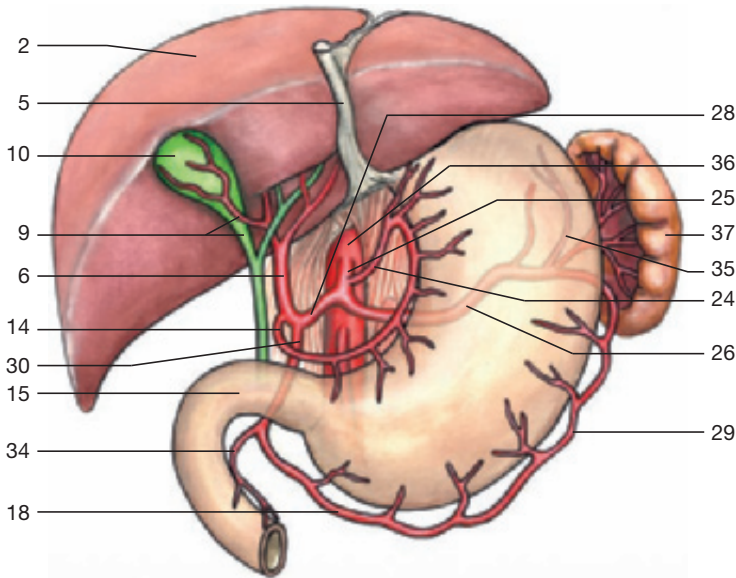
Upper abdominal organs (anterior aspect). Lesser sac. The gastrocolic ligament has been divided and the whole stomach raised to display the posterior wall of the lesser sac.



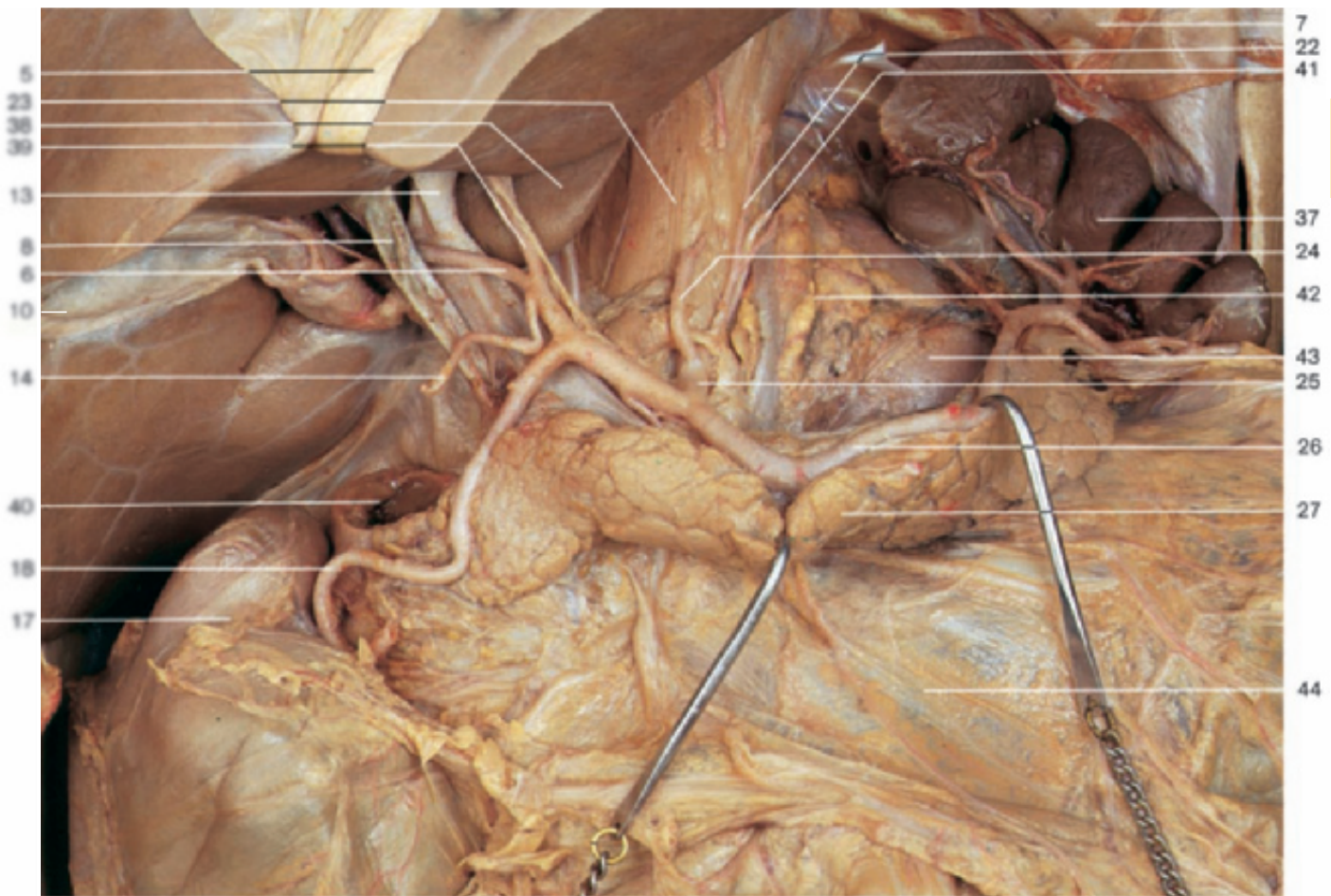
Midsagittal section through the abdominal cavity, demonstrating the site of lesser sac. Blue = lesser sac (omental bursa); green = peritoneum; arrow: entrance to the lesser sac (epiploic foramen).



Upper abdominal organs (anterior aspect). Celiac trunk. The lesser omentum has been removed and the lesser curvature of the stomach reflected to display the branches of the celiac trunk. The probe is situated within the epiploic foramen.

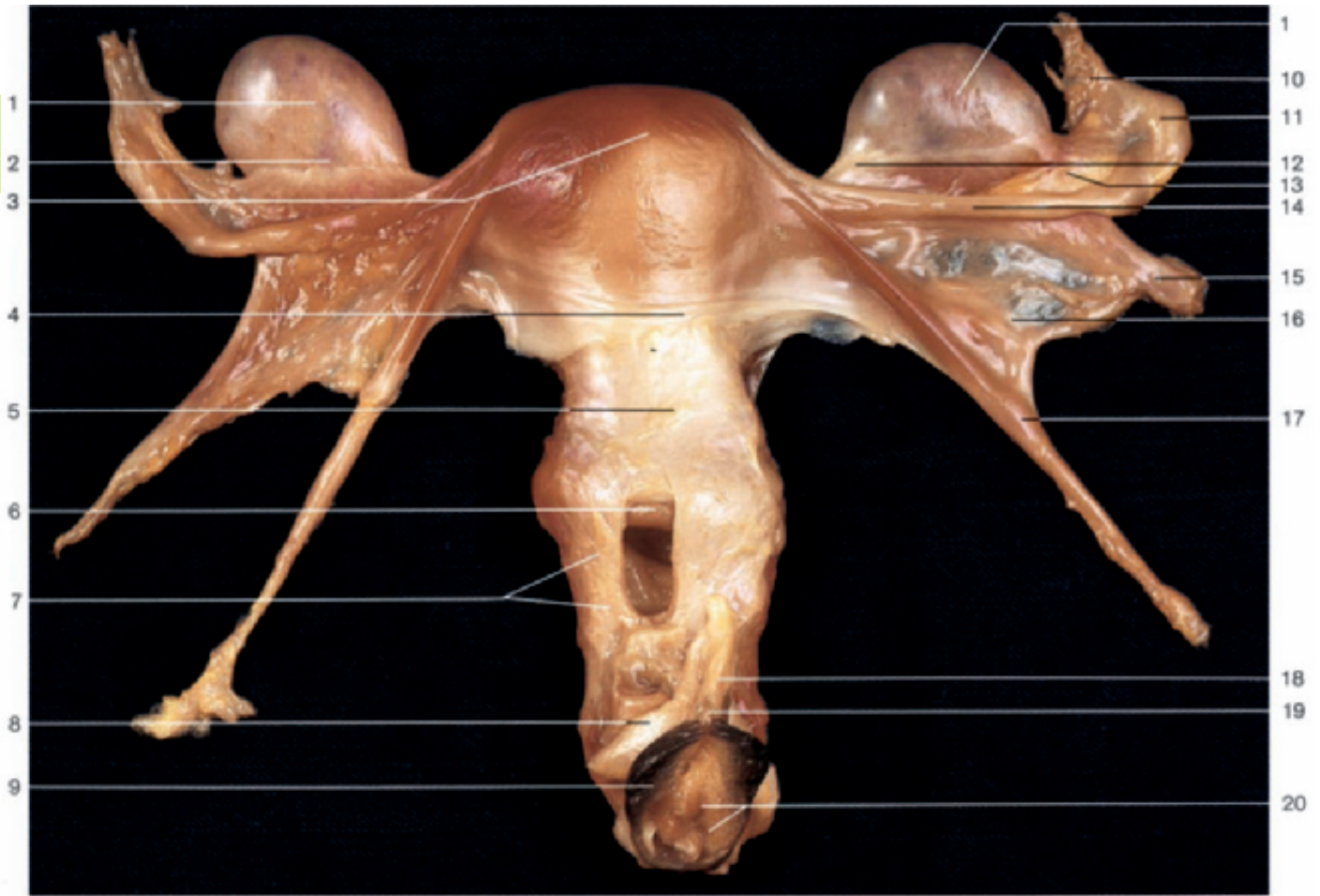
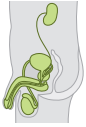

Arteries of upper abdominal organs and branches of celiac trunk.

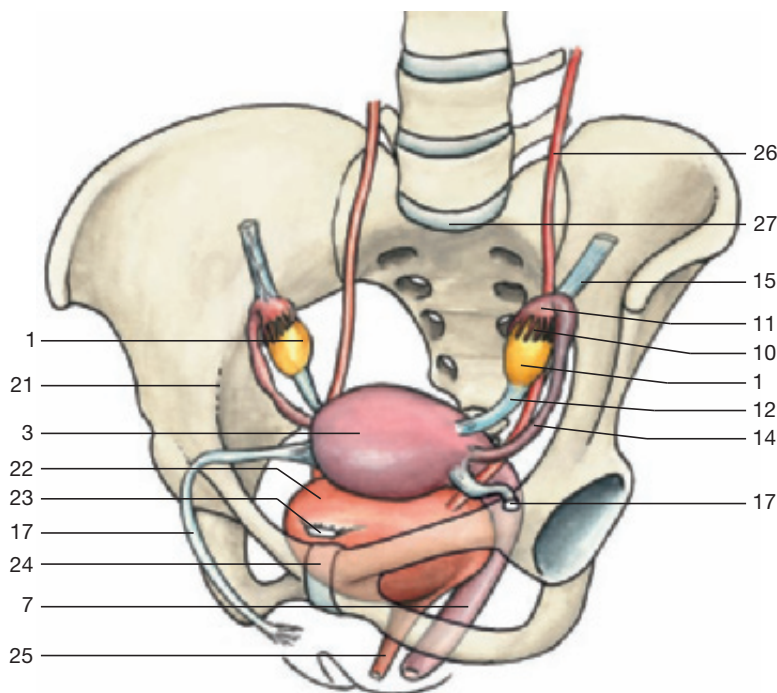


Upper abdominal organs (anterior aspect). Branches of celiac trunk; blood supply of liver, pancreas, and spleen. The stomach, superior part of duodenum, and celiac ganglion have been removed to reveal the anterior aspect of the posterior wall of the lesser sac (omental bursa) and the vessels and ducts of the hepatoduodenal ligament. The pancreas has been slightly reflected anteriorly.

- | | |
|--|---|
| 1 Lung | 23 Lumbar part of diaphragm |
| 2 Liver (visceral surface) | 24 Left gastric artery |
| 3 Lymph node | 25 Celiac trunk |
| 4 Inferior vena cava | 26 Splenic artery |
| 5 Ligamentum teres (reflected) | 27 Pancreas |
| 6 Right branch of hepatic artery proper | 28 Common hepatic artery |
| 7 Diaphragm | 29 Left gastro-omental (gastro-epiploic) artery |
| 8 Common hepatic duct (dilated) | 30 Gastroduodenal artery |
| 9 Cystic duct and artery | 31 Pyloric part of stomach |
| 10 Gallbladder | 32 Greater curvature of stomach |
| 11 Probe within the epiploic foramen | 33 Gastrocolic ligament |
| 12 Right lobe of liver | 34 Supraduodenal artery |
| 13 Portal vein | 35 Short gastric arteries |
| 14 Right gastric artery | 36 Aorta |
| 15 Duodenum | 37 Spleen |
| 16 Pylorus | 38 Caudate lobe of liver |
| 17 Right colic flexure | 39 Left branch of hepatic artery proper |
| 18 Right gastro-omental (gastro-epiploic) artery | 40 Descending part of duodenum (cut) |
| 19 Transverse colon | 41 Left inferior phrenic artery |
| 20 Abdominal part of esophagus (cardiac part of stomach) | 42 Suprarenal gland |
| 21 Fundus of stomach | 43 Kidney |
| 22 Esophageal branches of left gastric artery | 44 Transverse mesocolon |

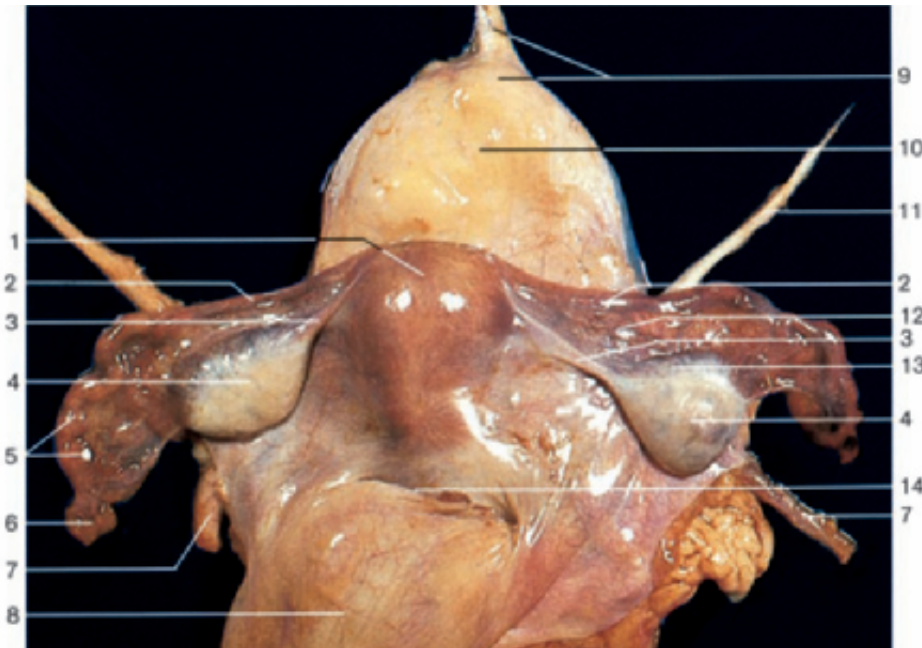
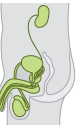

Female genital organs, isolated (anterior aspect). The anterior wall of the vagina has been opened to display the vaginal portion of the cervix.



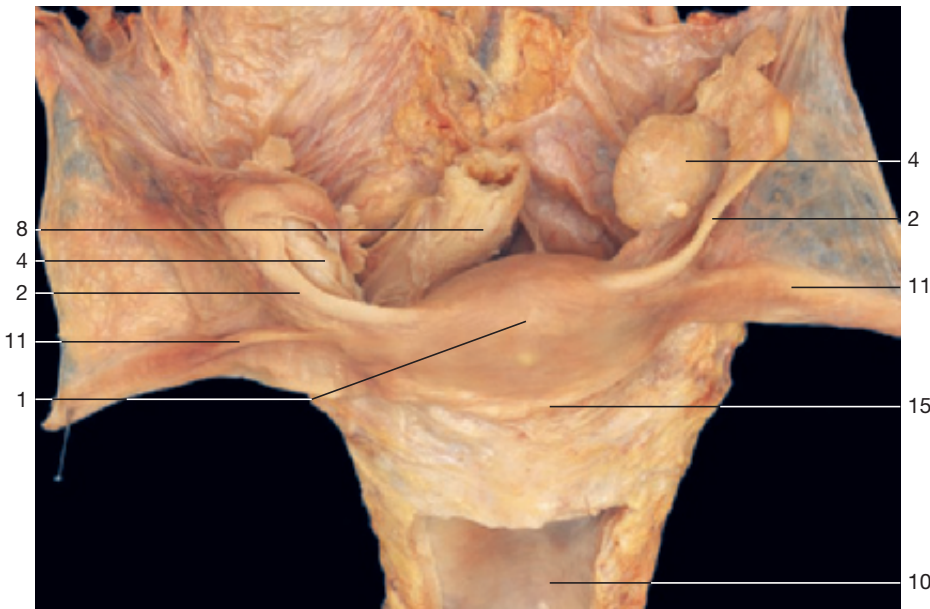
- 1 Ovary
- 2 Mesovarium
- 3 Fundus of uterus
- 4 Vesico-uterine pouch
- 5 Cervix of uterus
- 6 Vaginal portion of cervix
- 7 Vagina
- 8 Crus of clitoris
- 9 Labium minus
- 10 Fimbriae of uterine tube
- 11 Infundibulum of uterine tube
- 12 Ligament of the ovary
- 13 Mesosalpinx
- 14 Uterine tube
- 15 Suspensory ligament of ovary (caudally displaced)
- 16 Broad ligament of uterus
- 17 Round ligament of uterus
- 18 Corpus cavernosum of clitoris
- 19 Glans of clitoris
- 20 Hymen and vaginal orifice
- 21 Linea terminalis
- 22 Urinary bladder
- 23 Medial umbilical ligament
- 24 Pubic symphysis
- 25 Urethra
- 26 Ureter
- 27 Promontory

Position of female internal genital organs (oblique-anterior aspect).

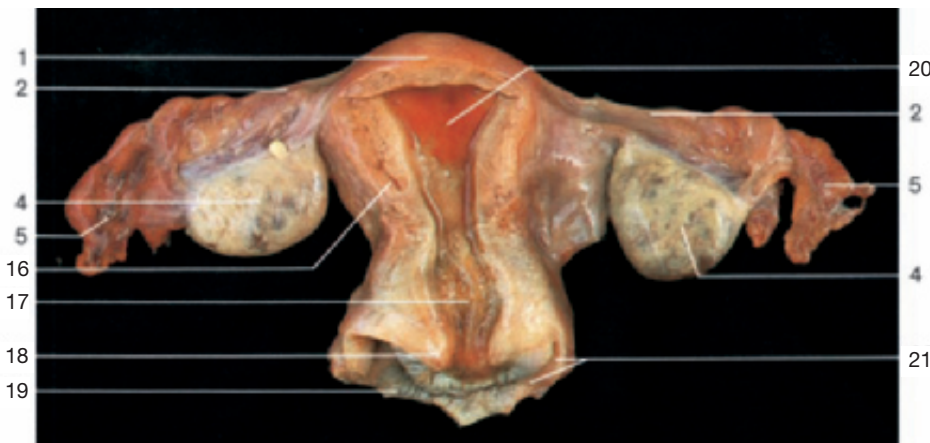

- 1 Fundus of uterus
- 2 Uterine tube
- 3 Ligament of the ovary
- 4 Ovary
- 5 Infundibulum of uterine tube
- 6 Fimbriae of uterine tube
- 7 Ureter
- 8 Rectum
- 9 Apex of urinary bladder and median umbilical ligament
- 10 Urinary bladder (fenestrated in the dissection in the middle)
- 11 Round ligament of uterus
- 12 Mesosalpinx
- 13 Mesovarium
- 14 Recto-uterine pouch (of Douglas)
- 15 Vesico-uterine pouch
- 16 Body of uterus
- 17 Cervix of uterus
- 18 Vaginal portion of cervix of uterus
- 19 Vagina
- 20 Mucous membrane of uterus congestion
- 21 Anterior fornix of vagina

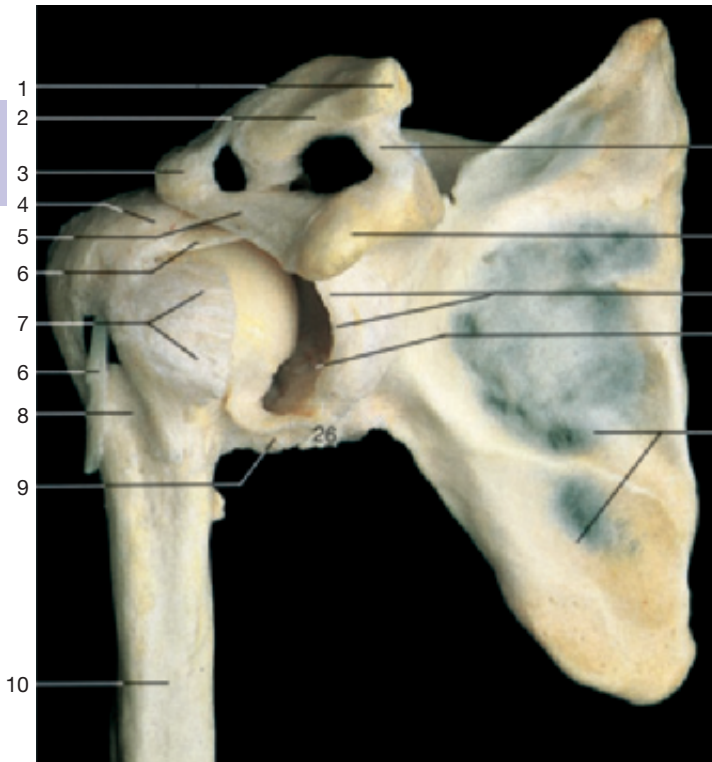
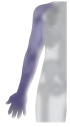Female genital organs, isolated (supero-posterior aspect).



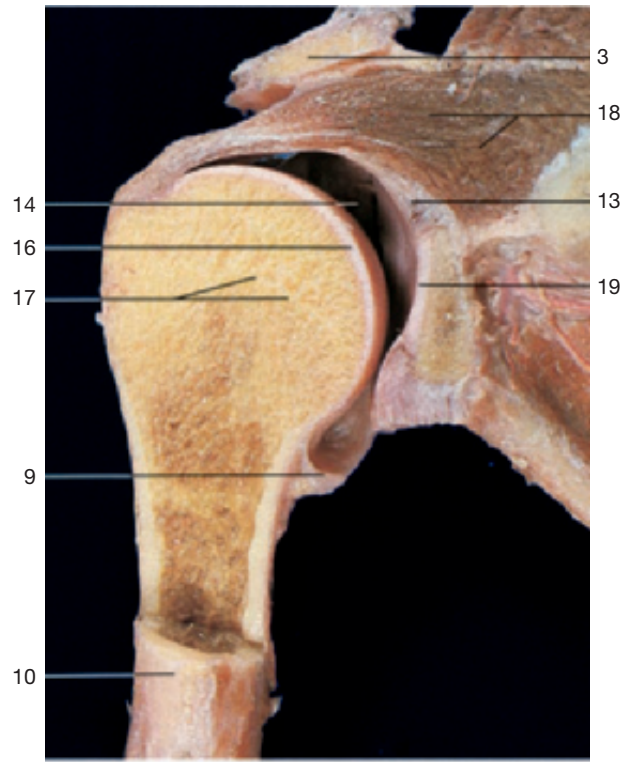
Uterus and related organs, isolated (superior aspect). The left ovary is enlarged.



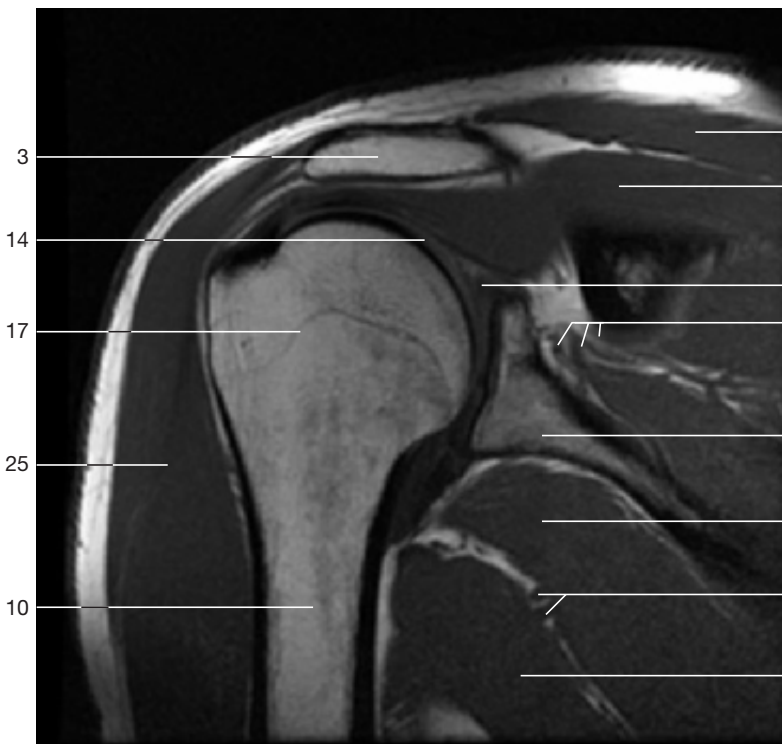
Uterus and related organs, isolated (posterior aspect). The posterior wall of the uterus has been opened.



Right shoulder joint. The anterior part of the articular capsule has been removed and the head of the humerus has been slightly rotated outward to show the cavity of the joint.

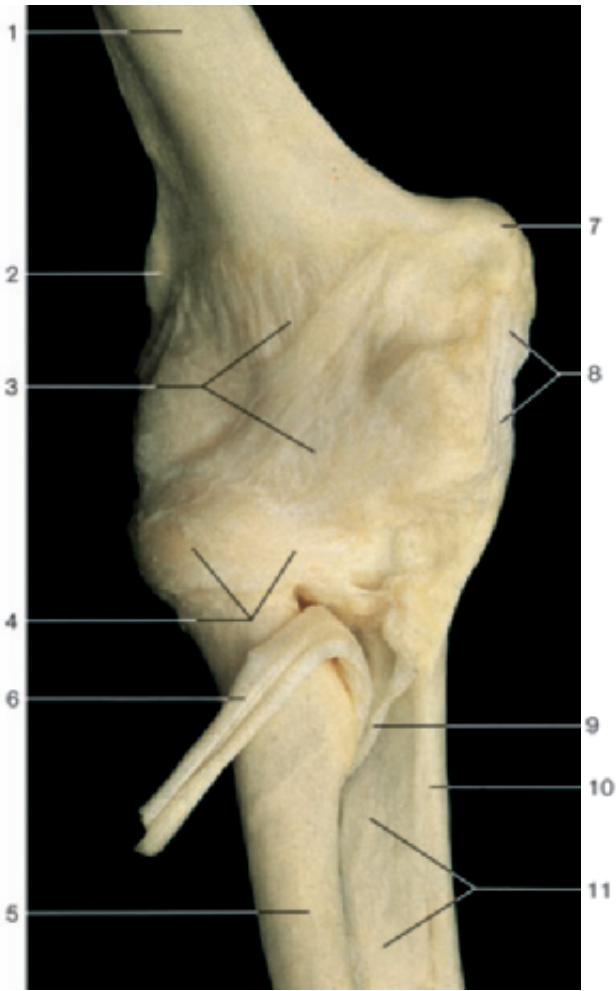


Coronal section through the right shoulder joint (anterior aspect).

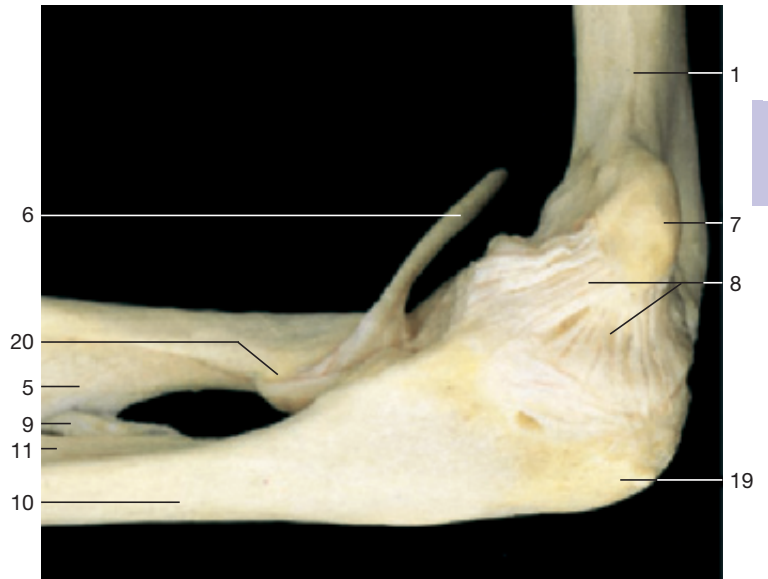


Coronal section through the right shoulder joint (MRI scan).
(Courtesy of Prof. Heuck, Munich, Germany.)

- 1 Acromial end of clavicle
- 2 Acromioclavicular joint
- 3 Acromion
- 4 Tendon of supraspinatus muscle (attached to the articular capsule)
- 5 Coraco-acromial ligament
- 6 Tendon of long head of biceps brachii muscle
- 7 Tendon of subscapularis muscle (attached to the articular capsule)
- 8 Intertubercular sulcus
- 9 Articular capsule of shoulder joint
- 10 Humerus
- 11 Trapezoid ligament
- 12 Coracoid process
- 13 Glenoid labrum
- 14 Shoulder joint (joint cavity)
- 15 Scapula
- 16 Head of humerus
- 17 Epiphysial line
- 18 Supraspinatus muscle
- 19 Glenoid cavity
- 20 Trapezius muscle
- 21 Suprascapular artery, vein, and nerve
- 22 Teres major muscle
- 23 Circumflexa scapular artery and vein
- 24 Latissimus dorsi muscle
- 25 Deltoid muscle
- 26 Tendon of long head of triceps brachii muscle

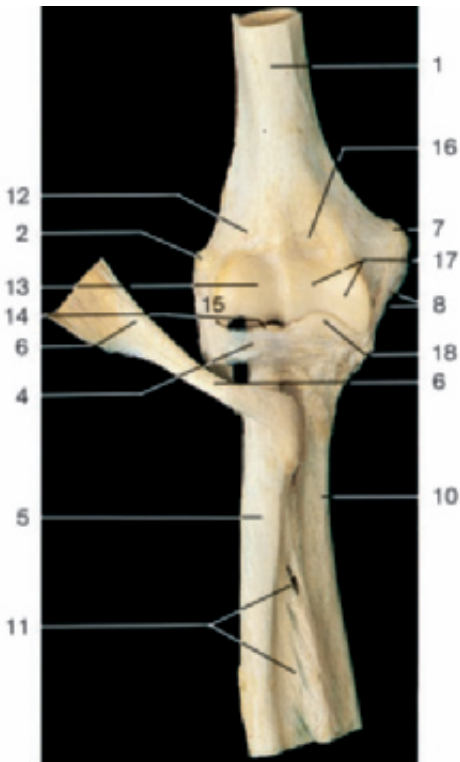


Ligaments of the elbow joint (anterior aspect).

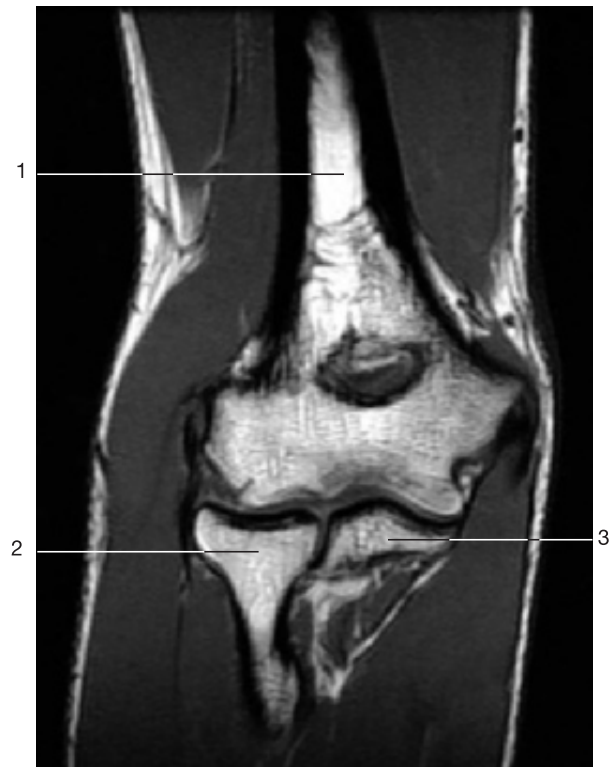

Ligaments of the elbow joint (medial aspect).

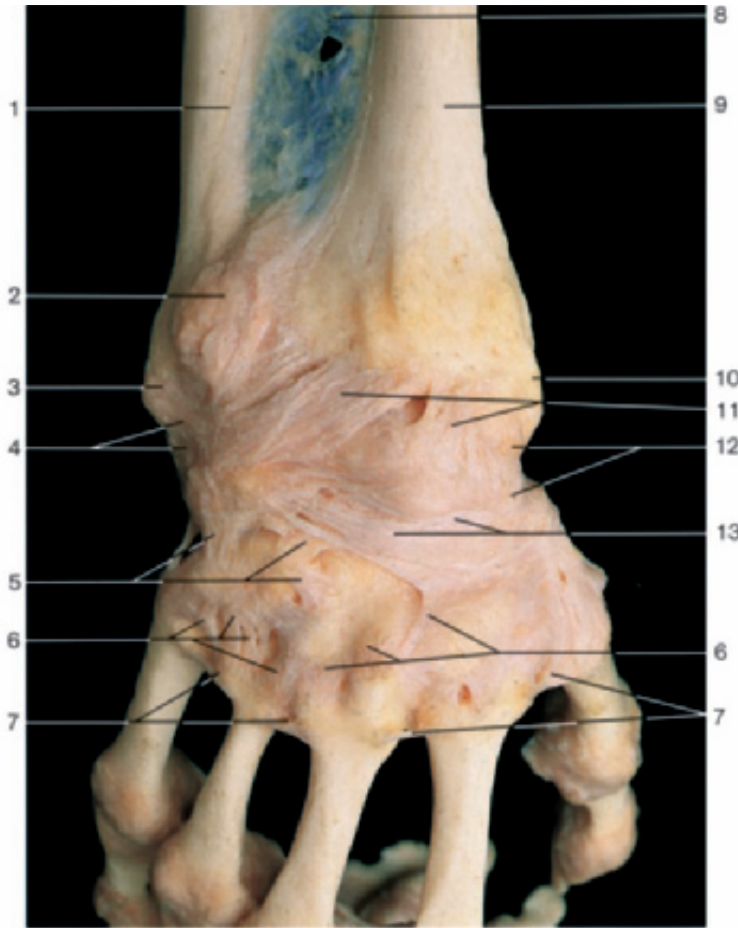
- | | |
|-----------------------------------|-------------------------------|
| 1 Humerus | 11 Interosseous membrane |
| 2 Lateral epicondyle of humerus | 12 Radial fossa |
| 3 Articular capsule | 13 Capitulum of humerus |
| 4 Anular ligament | 14 Head of radius |
| 5 Radius | 15 Radial collateral ligament |
| 6 Tendon of biceps brachii muscle | 16 Coronoid fossa |
| 7 Medial epicondyle of humerus | 17 Trochlea of humerus |
| 8 Ulnar collateral ligament | 18 Coronoid process of ulna |
| 9 Oblique chord | 19 Olecranon |
| 10 Ulna | 20 Radial tuberosity |



Elbow joint with ligaments (anterior aspect). Articular capsule has been removed to show the anular ligament.

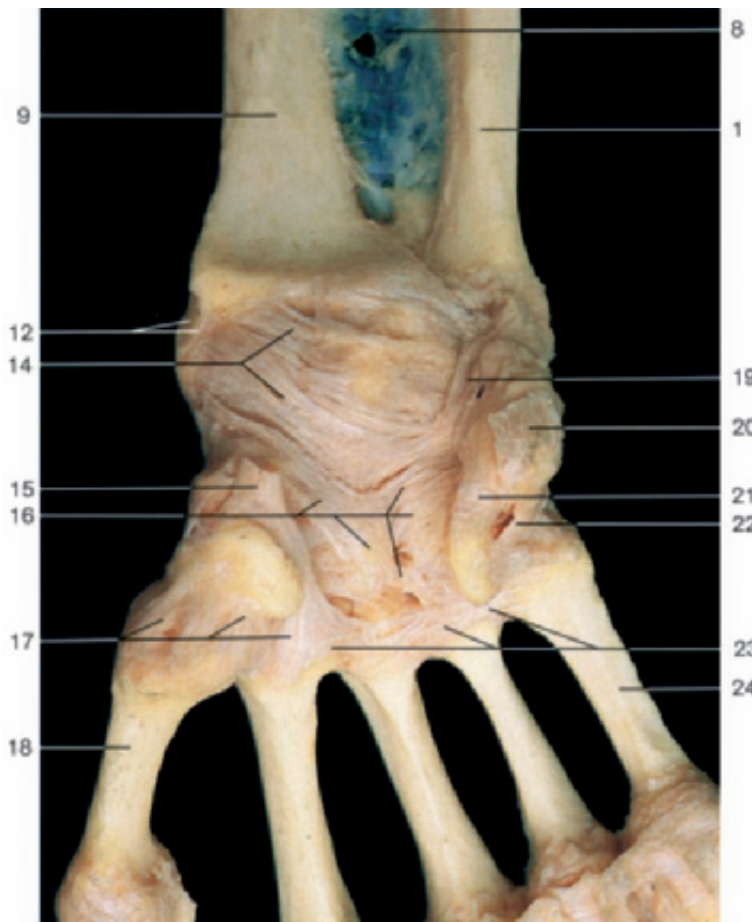


Coronal section through the elbow joint (MRI scan). (Courtesy of Prof. Heuck, Munich, Germany.)

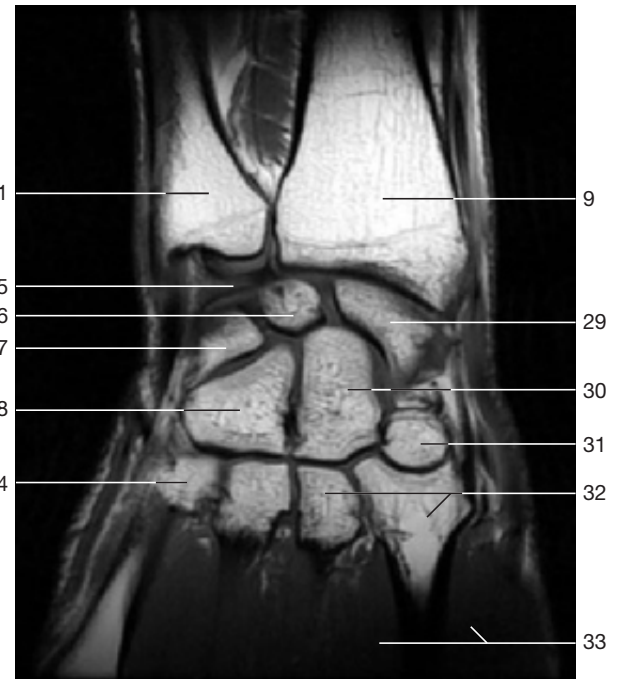


Ligaments of hand and wrist (dorsal aspect).

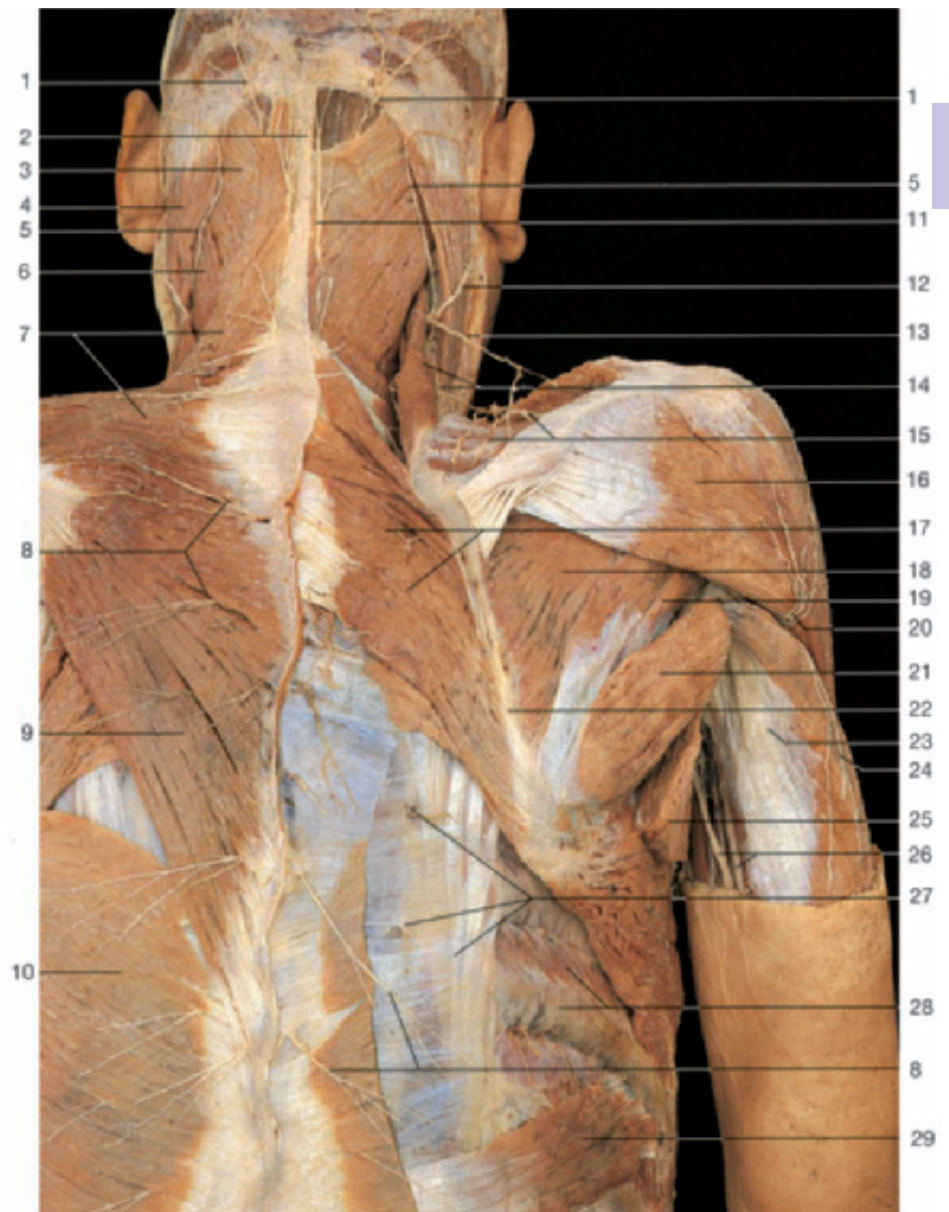
- 1 Ulna
- 2 Exostosis (pathological)
- 3 Head of ulna
- 4 Ulnar carpal collateral ligament
- 5 Deep intercarpal ligaments
- 6 Dorsal carpometacarpal ligaments
- 7 Dorsal metacarpal ligaments
- 8 Interosseous membrane
- 9 Radius
- 10 Styloid process of radius
- 11 Dorsal radiocarpal ligament
- 12 Radial collateral ligament
- 13 Articular capsule and dorsal intercarpal ligaments
- 14 Palmar radiocarpal ligament
- 15 Tendon of flexor carpi radialis muscle (cut)
- 16 Radiating carpal ligament
- 17 Palmar carpometacarpal ligaments
- 18 First metacarpal bone
- 19 Palmar ulnocarpal ligament
- 20 Tendon of flexor carpi ulnaris muscle (cut)
- 21 Pisohamate ligament
- 22 Pisometacarpal ligament
- 23 Palmar metacarpal ligaments
- 24 Fifth metacarpal bone
- 25 Articular disc (ulnocarpal)
- 26 Lunate bone
- 27 Triquetral bone
- 28 Hamate bone
- 29 Scaphoid (navicular) bone
- 30 Capitate bone
- 31 Trapezoid bone
- 32 Second and third metacarpal bones
- 33 Dorsal interossei muscles



Ligaments of hand and wrist (palmar aspect).

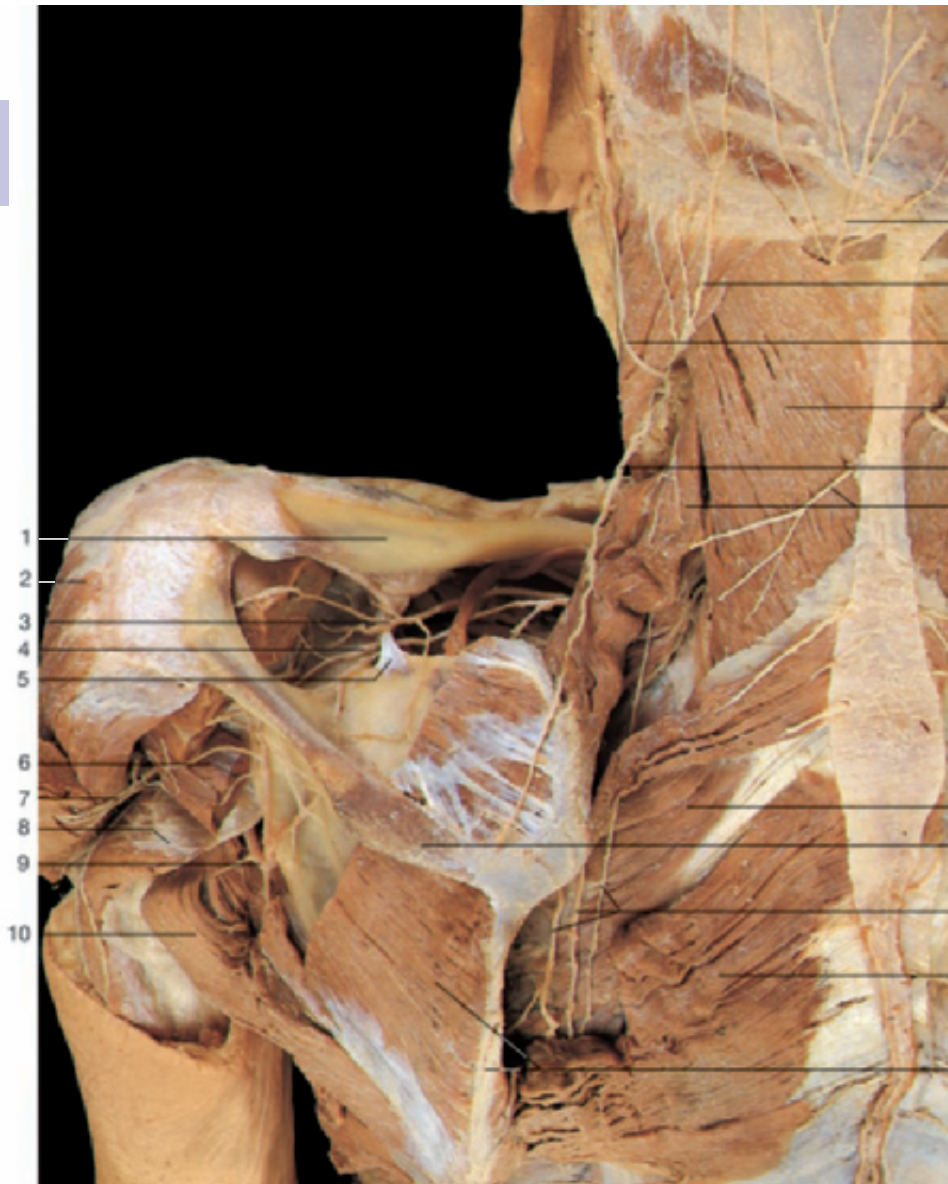


Coronal section through the hand and wrist (MRI scan). (Courtesy of Prof. Heuck, Munich, Germany.) Note the location of the wrist joint.



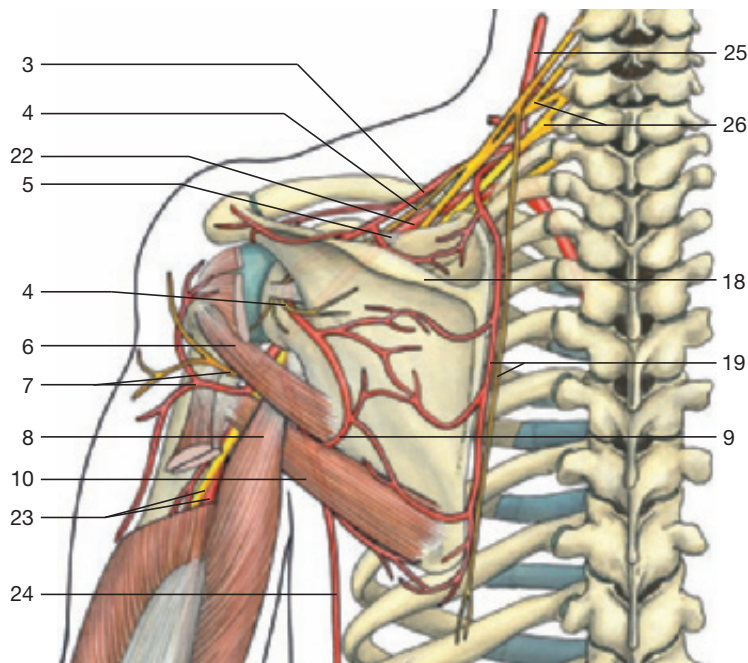
Posterior regions of neck and shoulder (left side: superficial layer; right side: trapezius and latissimus dorsi muscles have been removed). Dissection of dorsal branches of spinal nerves.

- | | |
|--|--|
| 1 Greater occipital nerve | 16 Deltoid muscle |
| 2 Ligamentum nuchae | 17 Rhomboid major muscle |
| 3 Splenius capitis muscle | 18 Infrapinatus muscle |
| 4 Sternocleidomastoid muscle | 19 Teres minor muscle |
| 5 Lesser occipital nerve | 20 Upper lateral cutaneous nerve of arm (branch of axillary nerve) |
| 6 Splenius cervicis muscle | 21 Teres major muscle |
| 7 Descending and transverse fibers of trapezius muscle | 22 Medial margin of scapula |
| 8 Medial cutaneous branches of dorsal rami of spinal nerves | 23 Long head of triceps muscle |
| 9 Ascending fibers of trapezius muscle | 24 Posterior cutaneous nerve of arm (branch of radial nerve) |
| 10 Latissimus dorsi muscle | 25 Latissimus dorsi muscle (divided) |
| 11 Cutaneous branch of third occipital nerve | 26 Ulnar nerve and brachial artery |
| 12 Great auricular nerve | 27 Lateral cutaneous branches of dorsal rami of spinal nerves and iliocostalis thoracis muscle |
| 13 Accessory nerve (n. XI) | 28 External intercostal muscle and seventh rib |
| 14 Posterior supraclavicular nerve and levator scapulae muscle | 29 Serratus posterior inferior muscle |
| 15 Branches of suprascapular artery | |

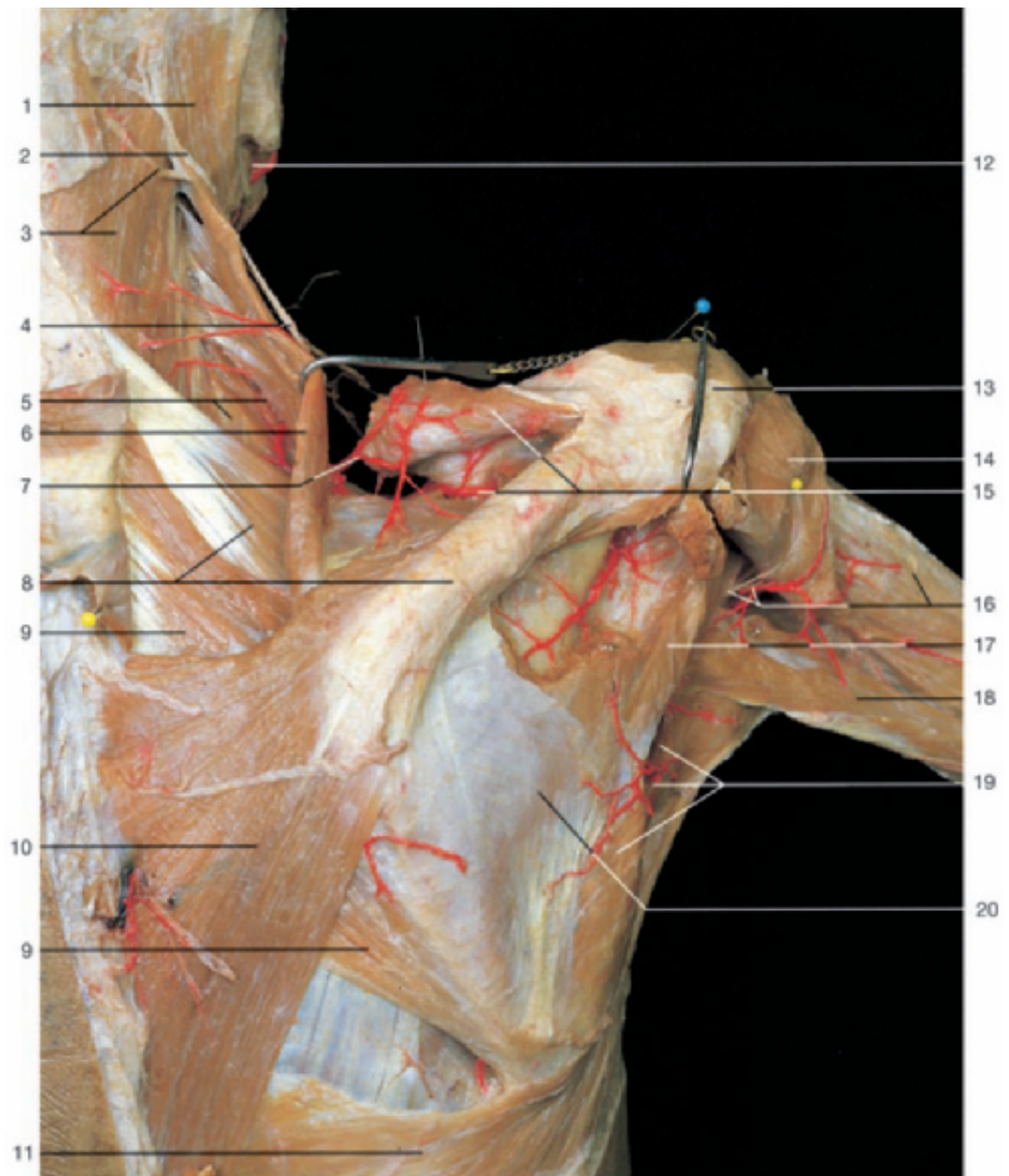


- 1 Clavicle
- 2 Deltoid muscle
- 3 Suprascapular artery
- 4 Suprascapular nerve
- 5 Superior transverse scapular ligament
- 6 Teres minor muscle
- 7 Axillary nerve and posterior circumflex humeral artery
- 8 Long head of triceps muscle
- 9 Circumflex scapular artery
- 10 Teres major muscle
- 11 Greater occipital nerve
- 12 Lesser occipital nerve
- 13 Great auricular nerve
- 14 Splenius capitis muscle
- 15 Accessory nerve (n. XI)
- 16 Third occipital nerve and levator scapulae muscle
- 17 Serratus posterior superior muscle
- 18 Spine of scapula
- 19 Descending scapular artery and dorsal scapular nerve
- 20 Rhomboid major muscle
- 21 Infraspinatus muscle and medial margin of scapula
- 22 Axillary artery
- 23 Radial nerve and brachial artery
- 24 Thoracodorsal artery
- 25 Thyrocervical trunk
- 26 Brachial plexus

Posterior region of the shoulder, deepest layer. Rhomboid and scapular muscles have been fenestrated, the posterior part of deltoid muscle has been reflected.

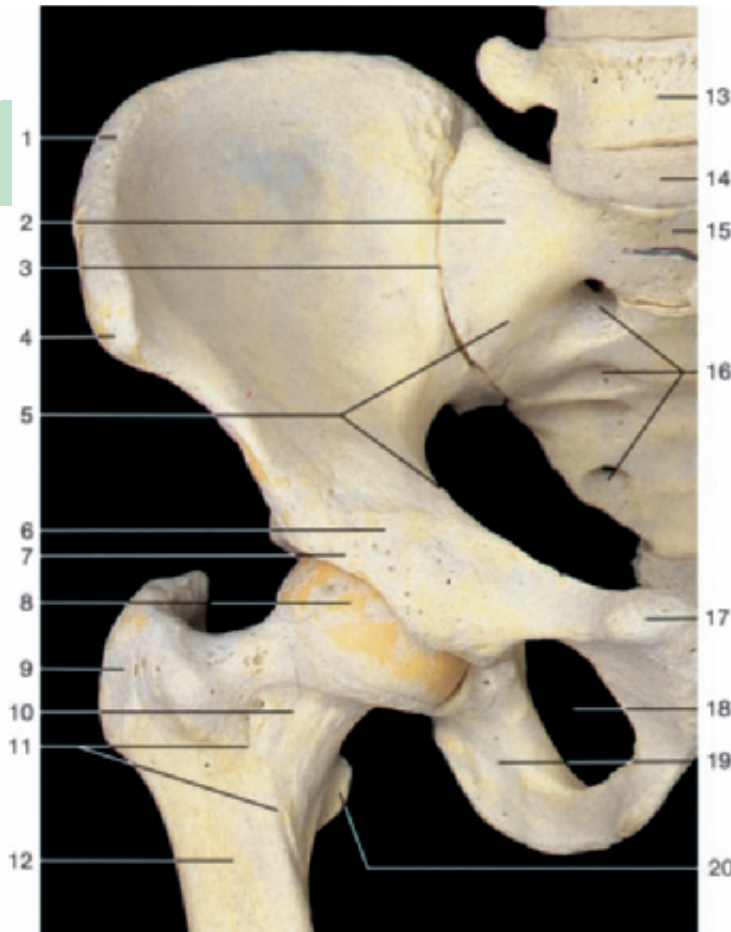


Collateral circulation of the shoulder (posterior aspect). Anastomosis of suprascapular and circumflex scapular arteries.



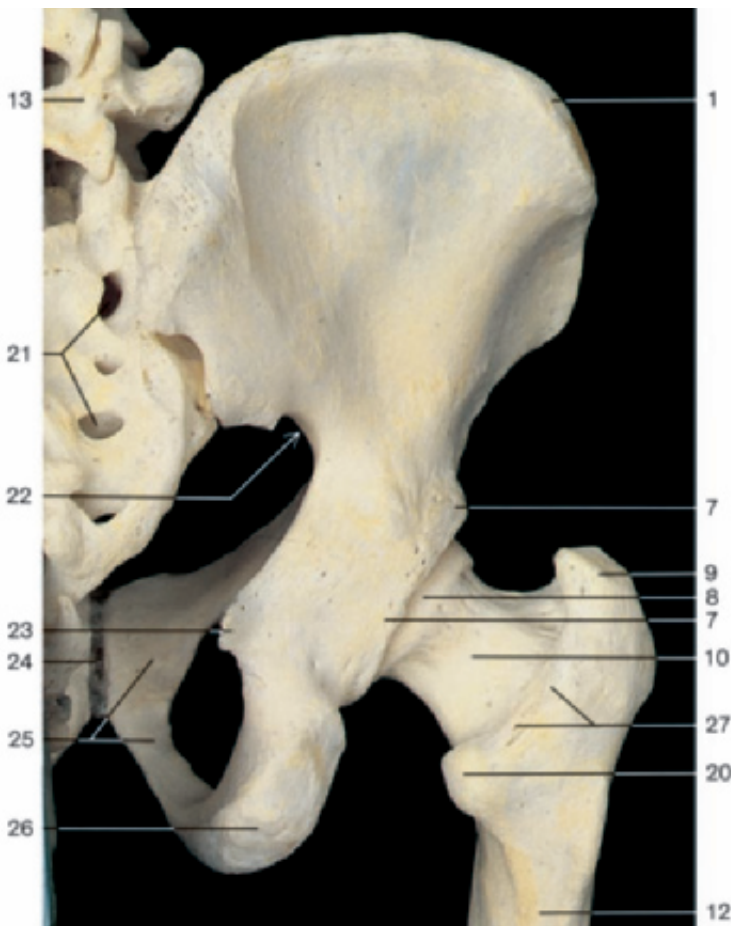Posterior region of the shoulder, deep layer. The arteries of the scapular region have been injected with red gelatin. Trapezius, deltoid, and infraspinatus muscles have been partially removed or reflected.

- | | |
|---|--|
| 1 Sternocleidomastoid muscle | 10 Trapezius muscle |
| 2 Lesser occipital nerve | 11 Latissimus dorsi muscle |
| 3 Splenius capitis muscle and third occipital nerve | 12 Facial artery |
| 4 Accessory nerve (n. XI) | 13 Acromion |
| 5 Splenius cervicis muscle and transverse cervical artery (deep branch) | 14 Deltoid muscle |
| 6 Levator scapulae muscle | 15 Suprascapular artery and supraspinatus muscle (reflected) |
| 7 Transverse cervical artery (superficial branch) | 16 Axillary nerve, posterior circumflex humeral artery, and lateral head of triceps brachii muscle |
| 8 Spine of scapula and serratus posterior superior muscle | 17 Teres minor muscle |
| 9 Rhomboid major muscle | 18 Long head of triceps brachii muscle |
| | 19 Circumflex scapular artery and teres major muscle |
| | 20 Infraspinatus muscle |



- 1 Iliac crest
- 2 Lateral part of sacrum (ala)
- 3 Position of sacro-iliac joint
- 4 Anterior superior iliac spine
- 5 Linea terminalis
- 6 Iliopubic eminence
- 7 Bony margin of acetabulum
- 8 Head of femur
- 9 Greater trochanter
- 10 Neck of femur
- 11 Intertrochanteric line
- 12 Shaft of femur
- 13 Fifth lumbar vertebra
- 14 Intervertebral disc between fifth lumbar vertebra and sacrum (imitation)
- 15 Sacral promontory
- 16 Anterior sacral foramina
- 17 Pubic tubercle
- 18 Obturator foramen
- 19 Ramus of ischium
- 20 Lesser trochanter
- 21 Posterior sacral foramina
- 22 Greater sciatic notch
- 23 Ischial spine
- 24 Pubic symphysis
- 25 Pubis
- 26 Ischial tuberosity
- 27 Intertrochanteric crest
- 28 Symphyseal surface

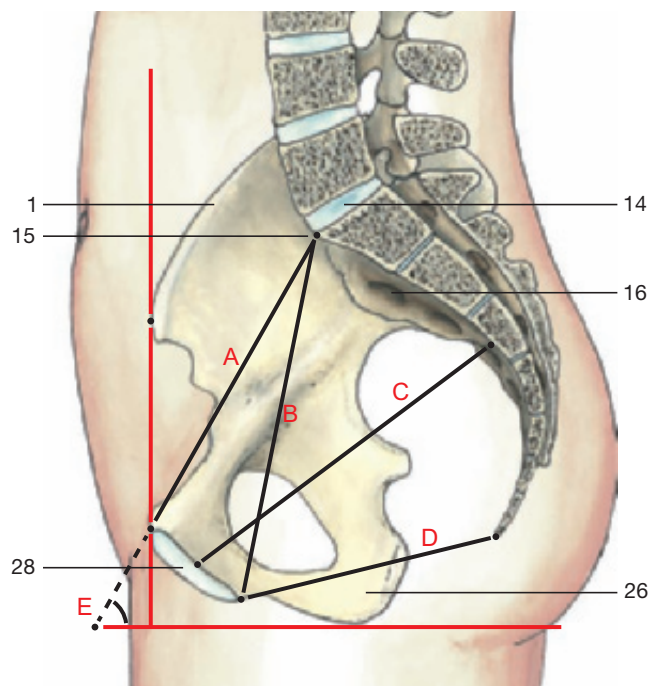
Bones of the right hip joint (anterior aspect).



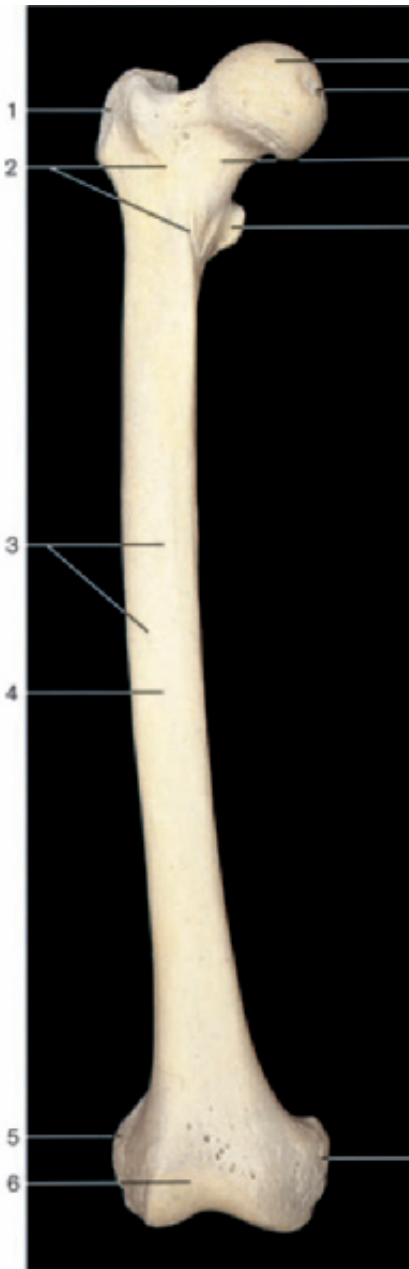
Bones of the right hip joint (posterior aspect).

Diameters of the pelvis

- A = True conjugate (11–11.5 cm) (conjugata vera)
- B = Diagonal conjugate (12.5–13 cm)
- C = Largest diameter of pelvis
- D = Inferior pelvic aperture
- E = Pelvic inclination (60°)

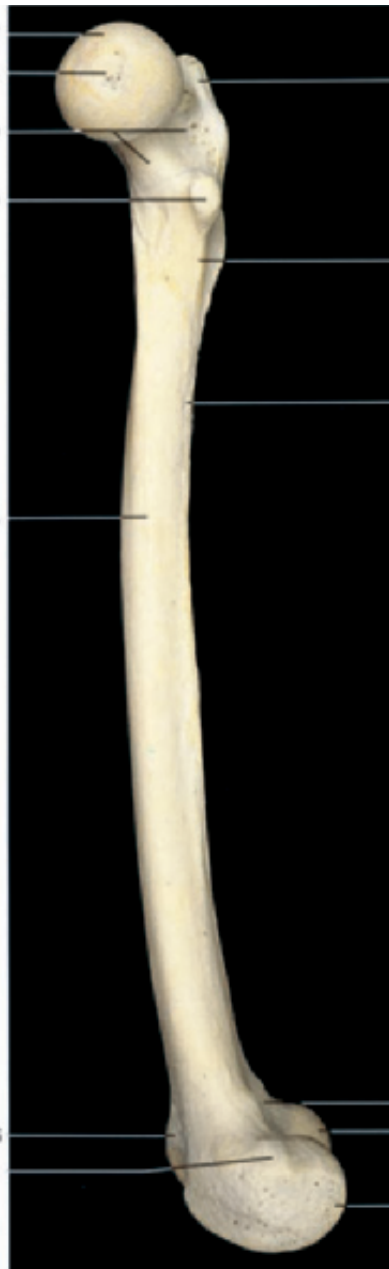

Inclination and diameters of the female pelvis, right half (medial aspect).



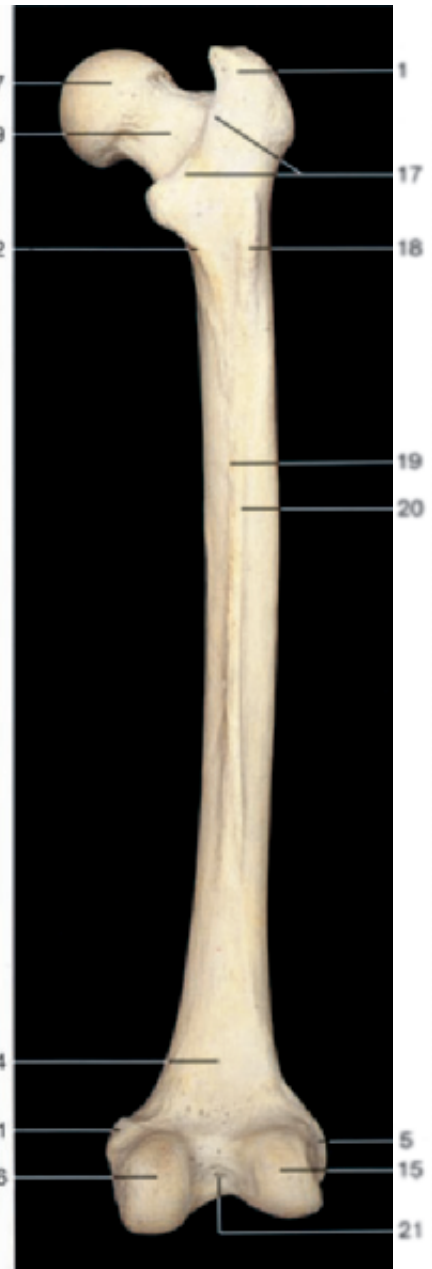Right femur (anterior aspect).

- 1 Greater trochanter
- 2 Intertrochanteric line
- 3 Nutrient foramina
- 4 Shaft of femur (diaphysis)
- 5 Lateral epicondyle
- 6 Patellar surface
- 7 Head



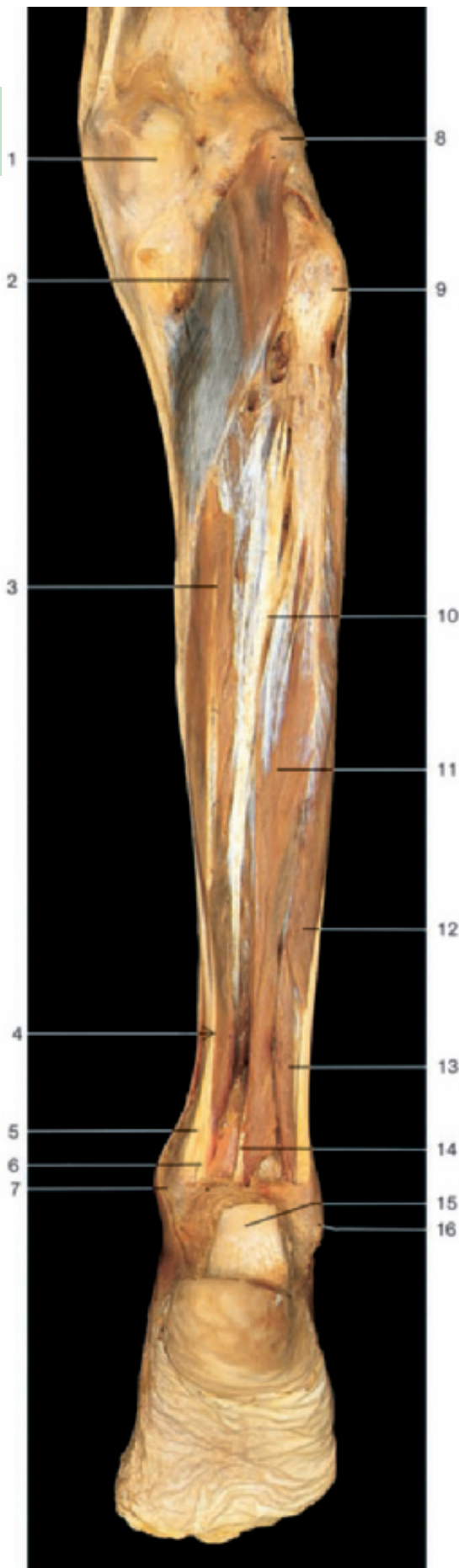
Right femur (medial aspect).

- 8 Fovea of head
- 9 Neck
- 10 Lesser trochanter
- 11 Medial epicondyle

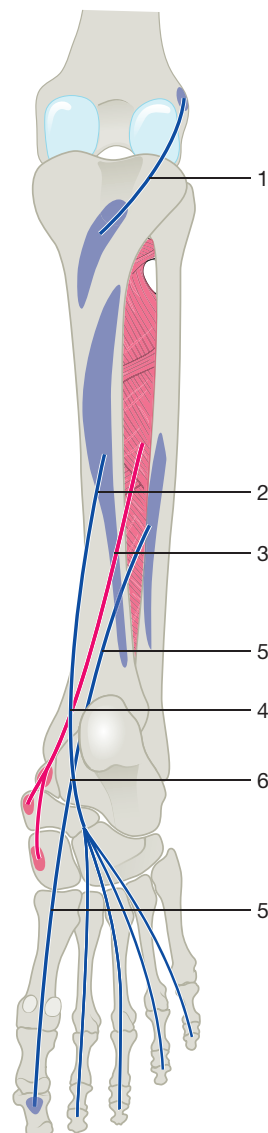


Right femur (posterior aspect).

- 12 Pectineal line
- 13 Linea aspera
- 14 Popliteal surface
- 15 Lateral condyle
- 16 Medial condyle
- 17 Intertrochanteric crest
- 18 Third trochanter
- 19 Medial lip of linea aspera
- 20 Lateral lip of linea aspera
- 21 Intercondylar fossa



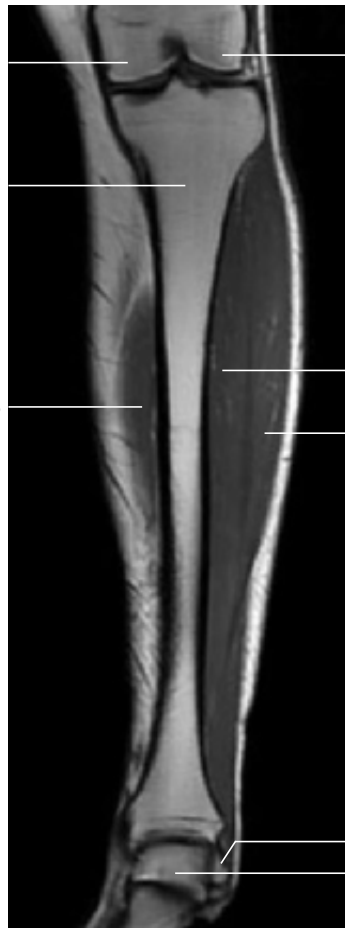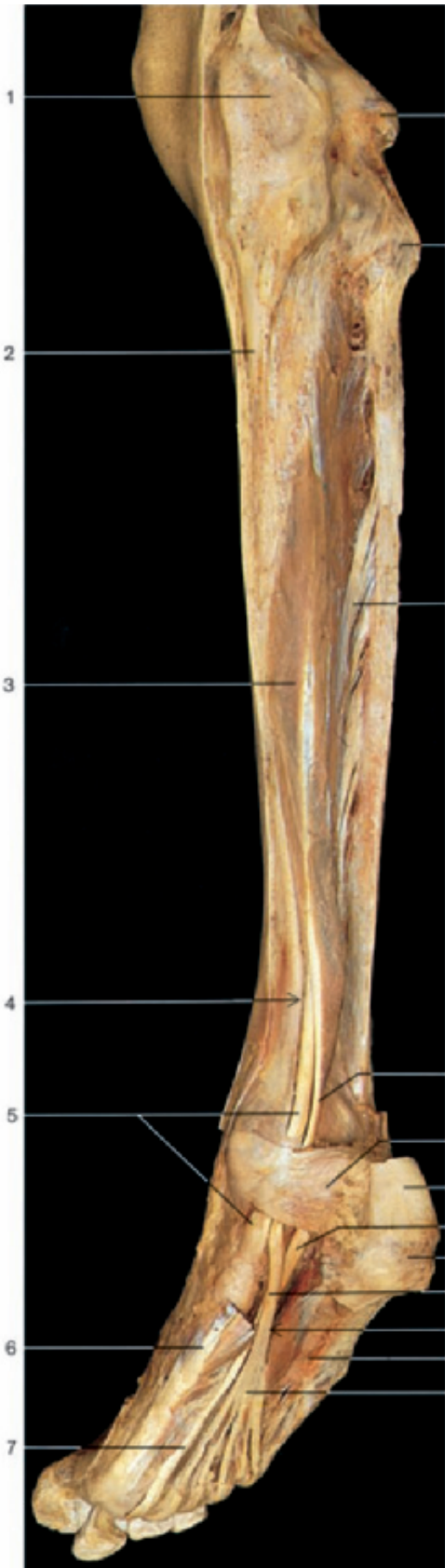- 1 Medial condyle of femur
- 2 Popliteus muscle
- 3 Flexor digitorum longus muscle
- 4 Crossing of tendons in the leg
- 5 Tendon of tibialis posterior muscle
- 6 Tendon of flexor digitorum longus muscle
- 7 Medial malleolus
- 8 Lateral condyle of femur
- 9 Head of fibula
- 10 Tibialis posterior muscle
- 11 Flexor hallucis longus muscle
- 12 Peroneus longus muscle
- 13 Peroneus brevis muscle
- 14 Tendon of flexor hallucis longus muscle
- 15 Calcaneal or Achilles tendon (divided)
- 16 Lateral malleolus



- 1 Popliteus muscle (blue)
- 2 Flexor digitorum longus muscle (blue)
- 3 Tibialis posterior muscle (red)
- 4 Crossing of tendons in the leg
- 5 Flexor hallucis longus muscle (blue)
- 6 Crossing of tendons in the sole

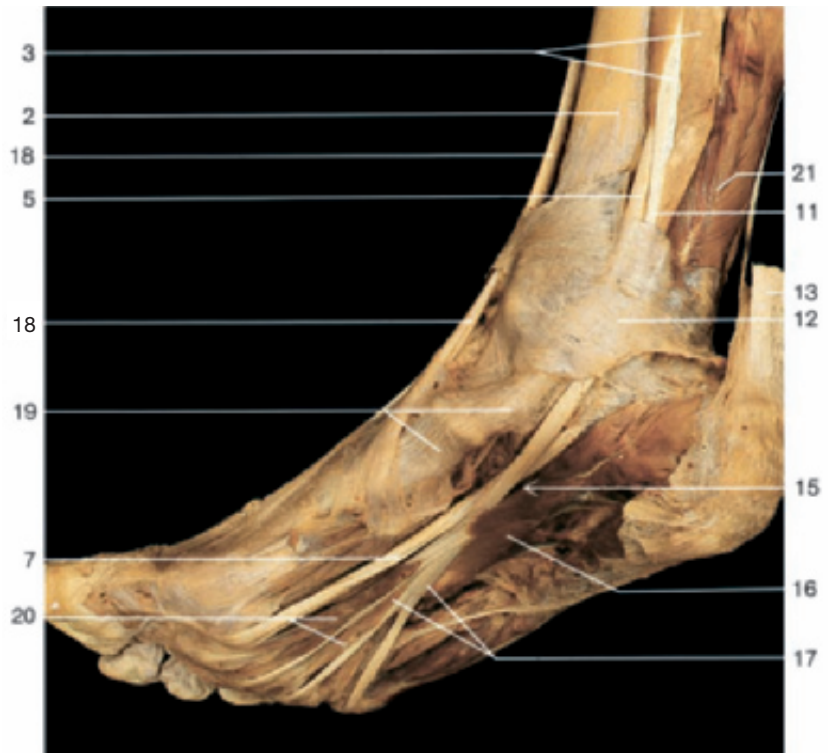Deep flexor muscles of leg and foot
(right side, posterior aspect).

Course of the deep flexor muscles of the leg (posterior aspect).



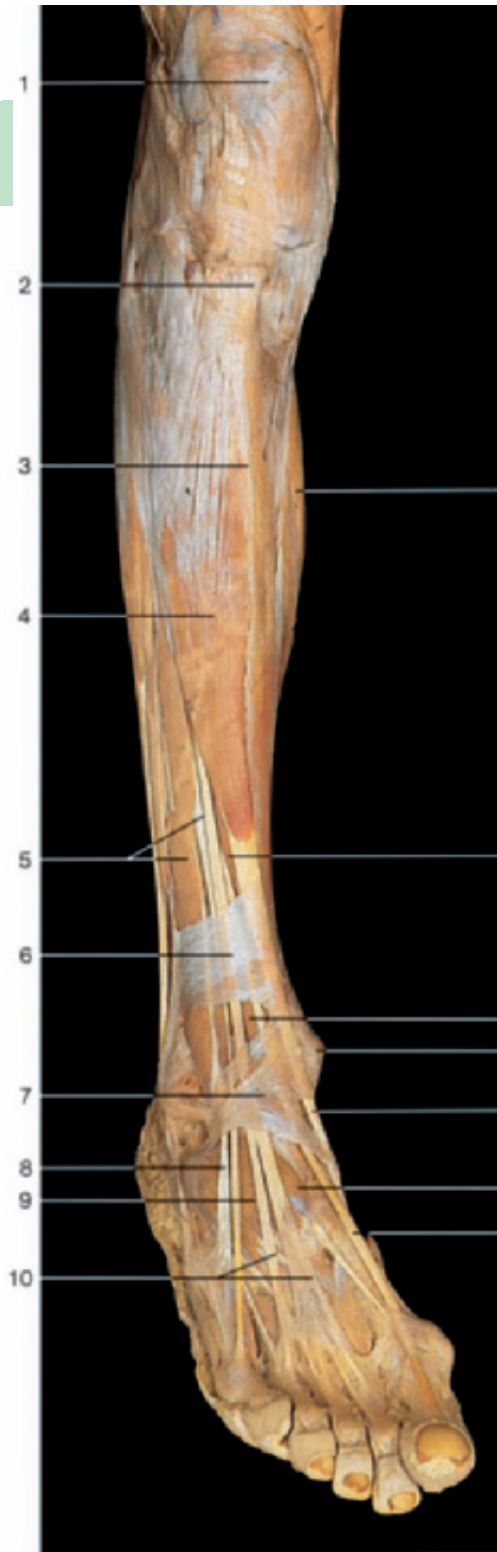- 1 Medial condyle of femur
- 2 Tibia
- 3 Flexor digitorum longus muscle
- 4 Crossing of tendons in the leg
- 5 Tendon of tibialis posterior muscle
- 6 Abductor hallucis muscle
- 7 Tendon of flexor hallucis longus muscle
- 8 Lateral condyle of femur
- 9 Head of fibula
- 10 Tibialis posterior muscle
- 11 Tendon of flexor digitorum longus muscle
- 12 Flexor retinaculum
- 13 Calcaneal or Achilles tendon
- 14 Calcaneal tuberosity
- 15 Crossing of tendons in the sole
- 16 Quadratus plantae muscle
- 17 Tendons of flexor digitorum longus muscle
- 18 Tendon of tibialis anterior muscle
- 19 Area of insertion of tibialis posterior muscle
- 20 Lumbrical muscles
- 21 Flexor hallucis longus muscle
- 22 Tibialis anterior muscle
- 23 Extensor hallucis longus muscle
- 24 Lateral malleolus of fibula
- 25 Trochlea of talus

Coronal section through the leg (MRI scan). (From Heuck et al., MRT-Atlas, 2009.)

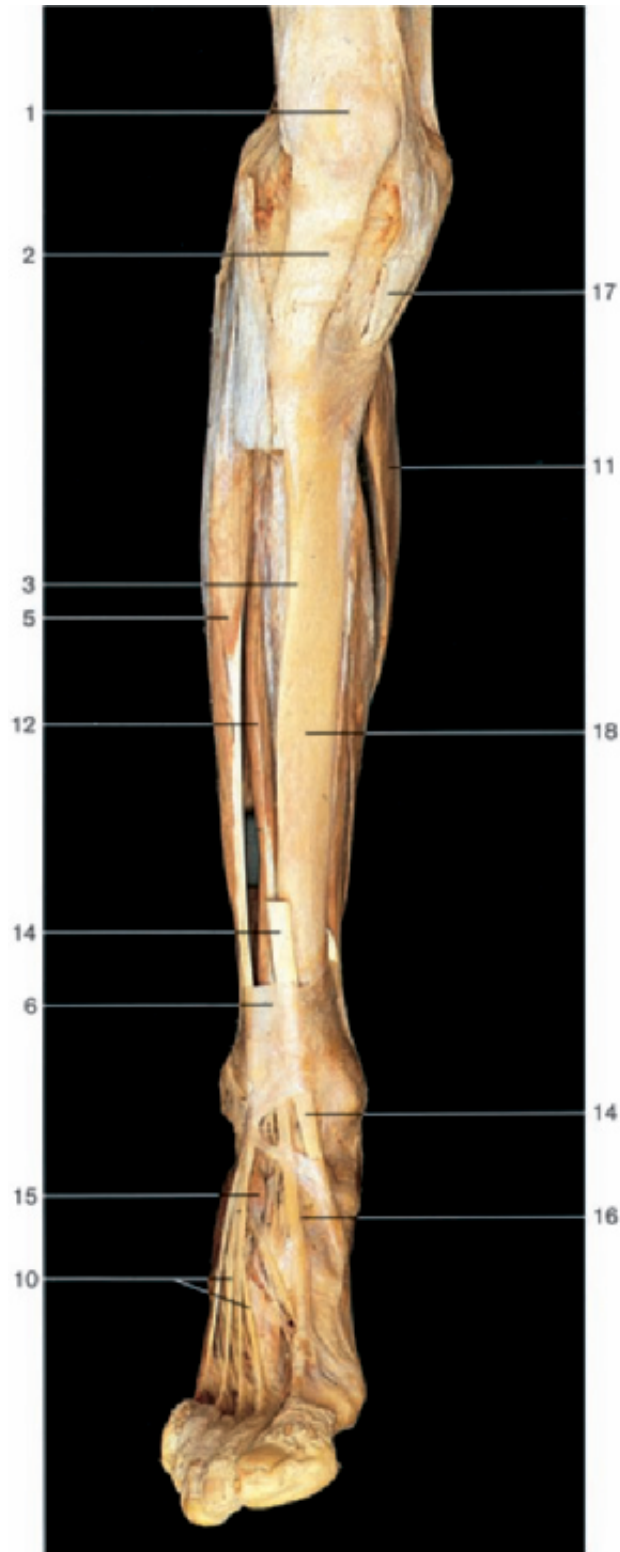


Sole of the right foot with tendons of long flexor muscles (oblique-medial and inferior aspect).

Deep flexor muscles of leg and foot (right side, posterior oblique-medial aspect). Flexor digitorum brevis and flexor hallucis longus muscles have been removed.

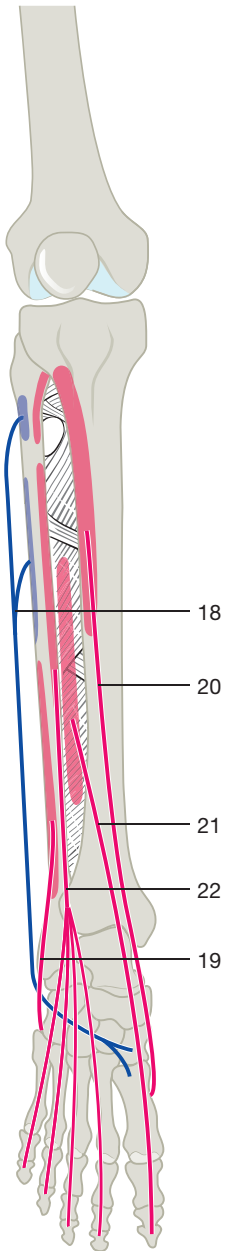


Extensor muscles of leg and foot (right side, oblique antero-lateral aspect).

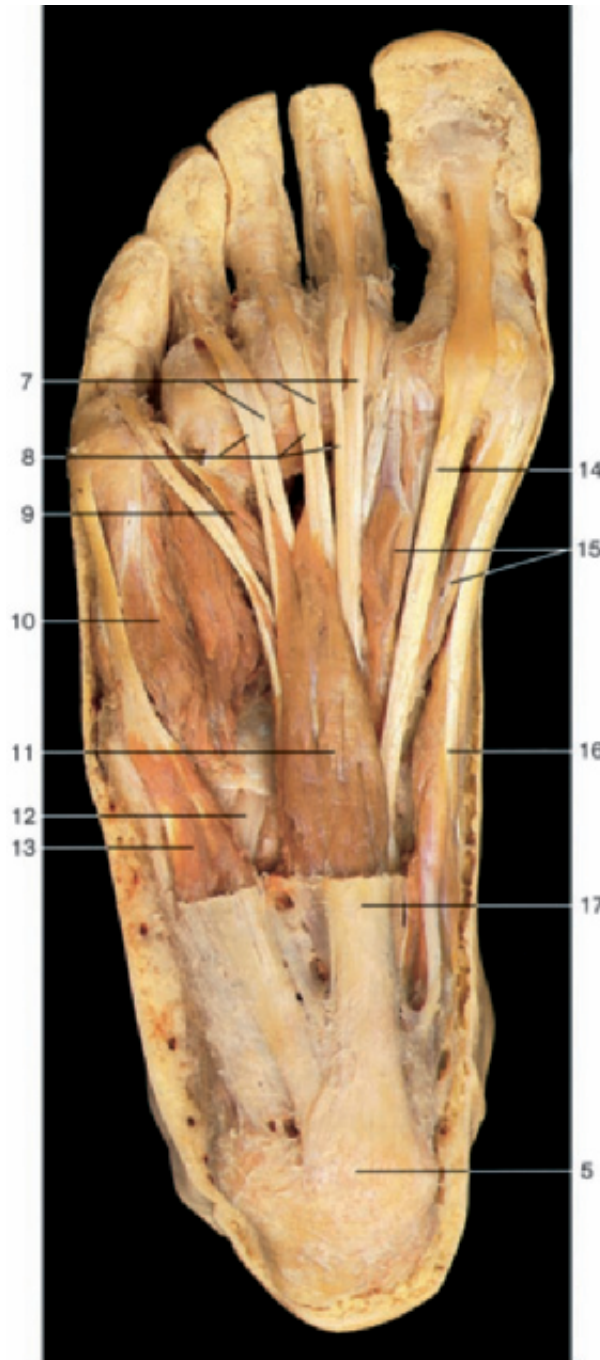


Extensor muscles of leg and foot (right side, anterior aspect). Part of the tibialis anterior muscle has been removed.

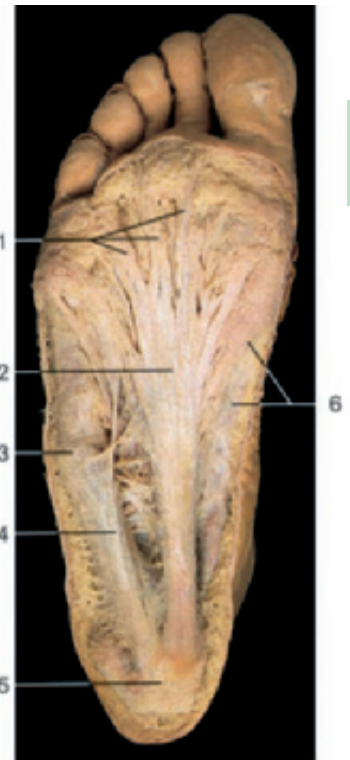- | | | |
|------------------------------------|--|---|
| 1 Patella | 8 Tendon of peroneus tertius muscle | 14 Tendon of tibialis anterior muscle |
| 2 Patellar ligament | 9 Extensor digitorum brevis muscle | 15 Extensor hallucis brevis muscle |
| 3 Anterior margin of tibia | 10 Tendons of extensor digitorum longus muscle | 16 Tendon of extensor hallucis longus muscle |
| 4 Tibialis anterior muscle | 11 Soleus muscle | 17 Common tendon of gracilis, semitendinosus, and sartorius muscles (pes anserinus) |
| 5 Extensor digitorum longus muscle | 12 Extensor hallucis longus muscle | 18 Tibia |
| 6 Superior extensor retinaculum | 13 Medial malleolus | |
| 7 Inferior extensor retinaculum | | |



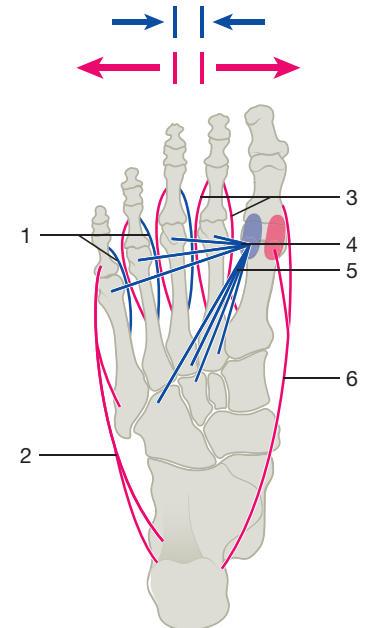
Course of the extensor muscles of the leg (anterior aspect).



Muscles of the sole of foot, superficial layer. The plantar aponeurosis and the fasciae of the superficial muscles have been removed.



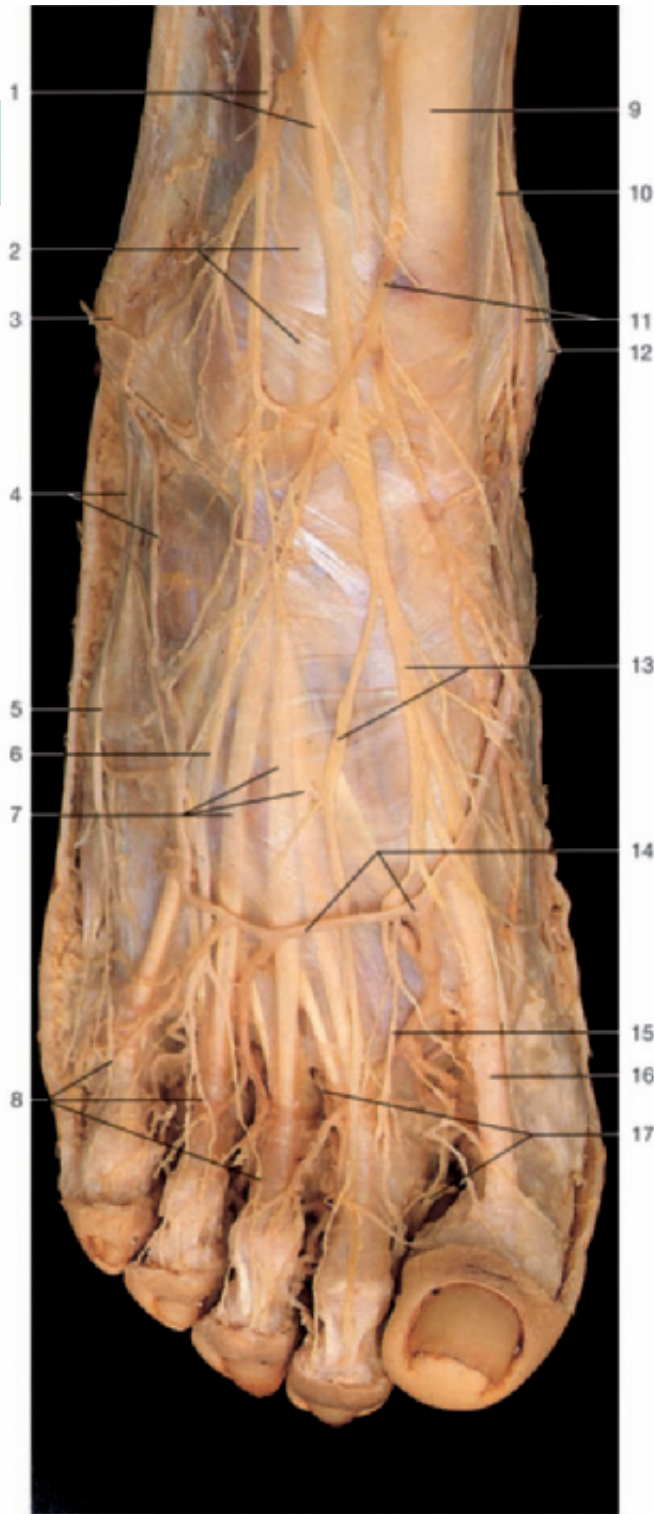
Sole of the foot with the plantar aponeurosis.



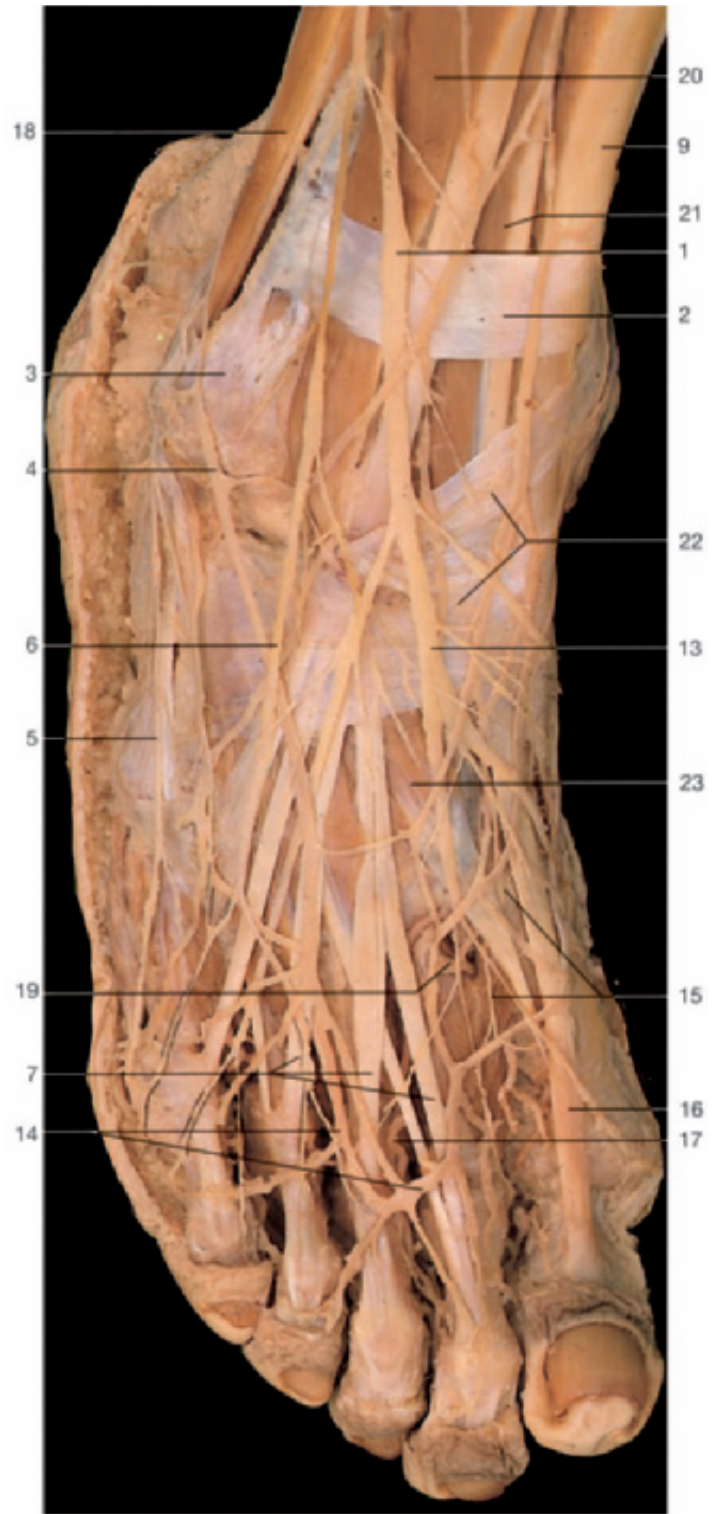Course of abductor and adductor muscles of the foot (plantar aspect). Red arrows: abduction; blue arrows: adduction.

- | | |
|---|--|
| 1 Longitudinal bands of plantar aponeurosis | 12 Tendon of peroneus longus muscle |
| 2 Plantar aponeurosis | 13 Abductor digiti minimi muscle |
| 3 Position of tuberosity of fifth metatarsal bone | 14 Tendon of flexor hallucis longus muscle |
| 4 Muscles of fifth toe with fascia | 15 Flexor hallucis brevis muscle |
| 5 Calcaneal tuberosity | 16 Abductor hallucis muscle |
| 6 Muscles of great toe with fascia | 17 Plantar aponeurosis (cut) |
| 7 Tendons of flexor digitorum longus muscle | 18 Peroneus longus muscle |
| 8 Tendons of flexor digitorum brevis muscle | 19 Peroneus brevis muscle |
| 9 Lumbrical muscle | 20 Tibialis anterior muscle |
| 10 Flexor digiti minimi brevis muscle | 21 Extensor hallucis longus muscle |
| 11 Flexor digitorum brevis muscle | 22 Extensor digitorum longus muscle |

- | |
|--|
| 1 Plantar interossei muscles (blue) |
| 2 Abductor digiti minimi muscle (red) |
| 3 Dorsal interossei muscles (red) |
| 4 Transverse head of adductor hallucis muscle (blue) |
| 5 Oblique head of adductor hallucis muscle (blue) |
| 6 Abductor hallucis muscle (red) |



Dorsum of the right foot, superficial layer.

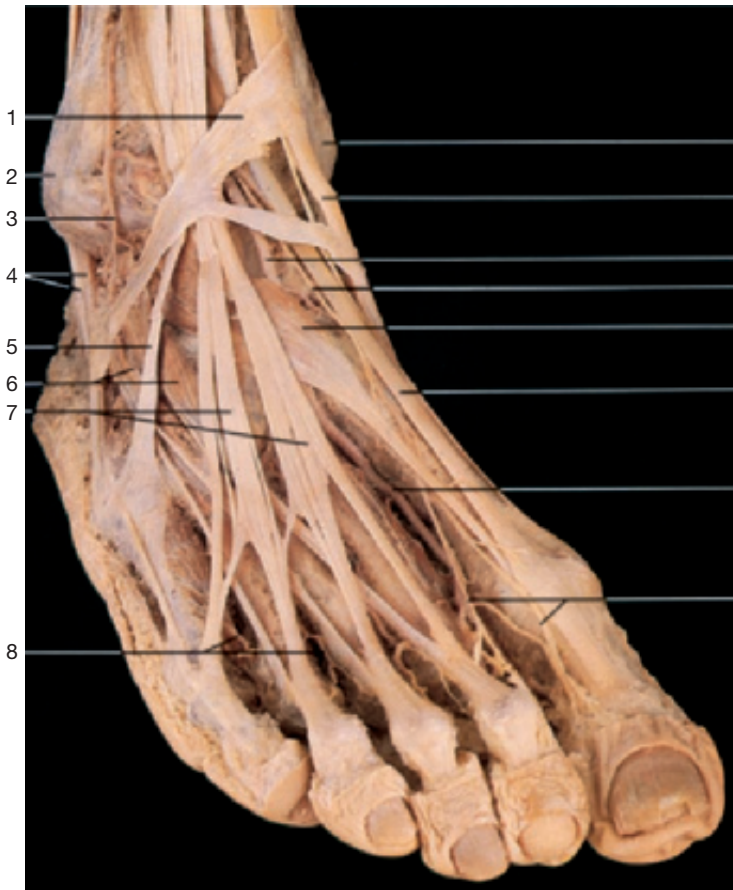

Dorsum of the right foot, superficial layer. The fascia of the dorsum has been removed.

- 1 Superficial fibular nerve
- 2 Superior extensor retinaculum
- 3 Lateral malleolus
- 4 Venous network of lateral malleolus and tributaries of small saphenous vein
- 5 Lateral dorsal cutaneous branch of sural nerve
- 6 Intermediate dorsal cutaneous nerve
- 7 Tendons of extensor digitorum longus muscle
- 8 Dorsal digital nerves

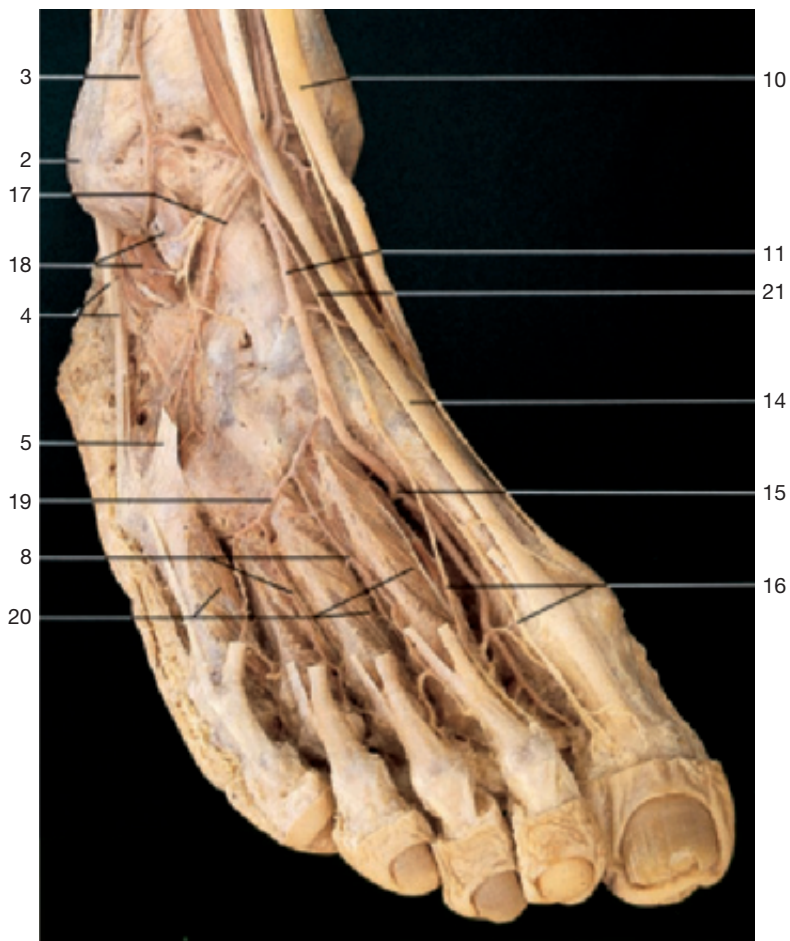- 9 Tendon of tibialis anterior muscle
- 10 Saphenous nerve
- 11 Venous network of medial malleolus and tributaries of great saphenous vein
- 12 Medial malleolus
- 13 Medial dorsal cutaneous nerves
- 14 Dorsal venous arch of foot
- 15 Dorsal digital nerve (of deep fibular nerve)
- 16 Tendon of extensor hallucis longus muscle

- 17 Dorsal digital arteries
- 18 Peroneal muscles
- 19 Deep plantar branch of dorsalis pedis artery anastomosing with plantar arch
- 20 Extensor digitorum longus muscle
- 21 Extensor hallucis longus muscle
- 22 Inferior extensor retinaculum
- 23 Extensor hallucis brevis muscle

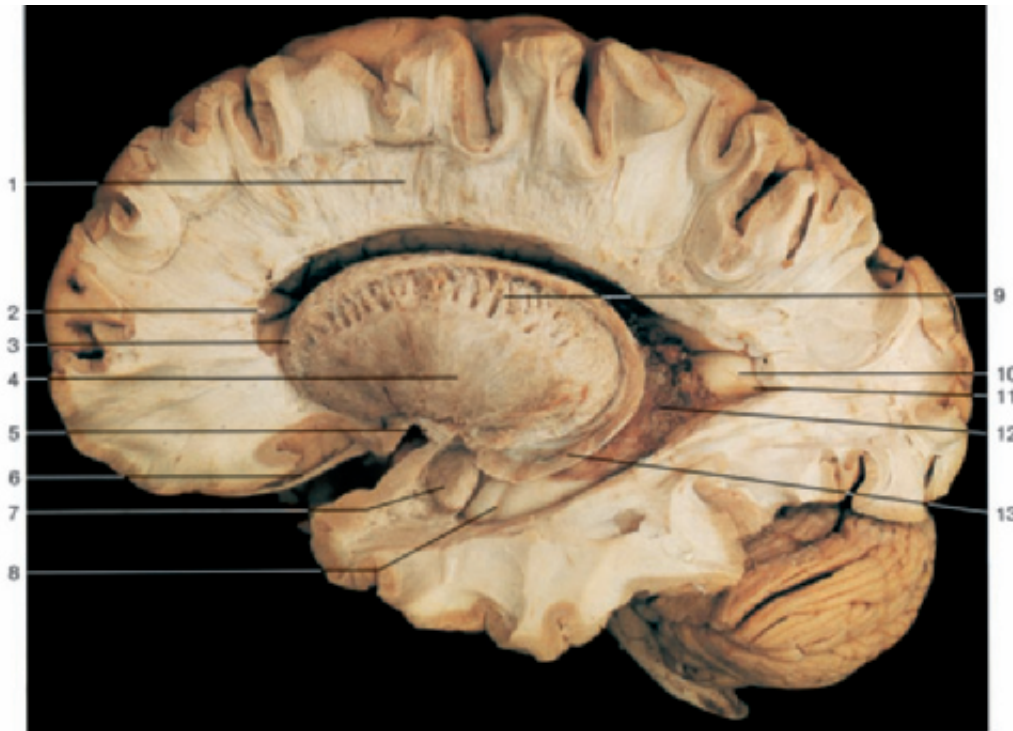
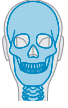

- 1 Inferior extensor retinaculum
- 2 Lateral malleolus
- 3 Lateral anterior malleolar artery
- 4 Tendons of peroneal muscles
- 5 Tendon of peroneus tertius muscle
- 6 Extensor digitorum brevis muscle
- 7 Tendons of extensor digitorum longus muscle
- 8 Dorsal metatarsal arteries
- 9 Medial malleolus
- 10 Tendon of tibialis anterior muscle
- 11 Dorsalis pedis artery
- 12 Deep fibular nerve (on dorsum of foot)
- 13 Extensor hallucis brevis muscle
- 14 Tendon of extensor hallucis longus muscle
- 15 Dorsalis pedis artery with deep plantar branch to the plantar arch
- 16 Terminal branches of deep fibular nerve
- 17 Lateral tarsal artery
- 18 Extensor digitorum brevis muscle (divided)
- 19 Arcuate artery
- 20 Dorsal interossei muscles
- 21 Deep fibular nerve

Dorsum of the right foot, middle layer. The cutaneous nerves have been removed.

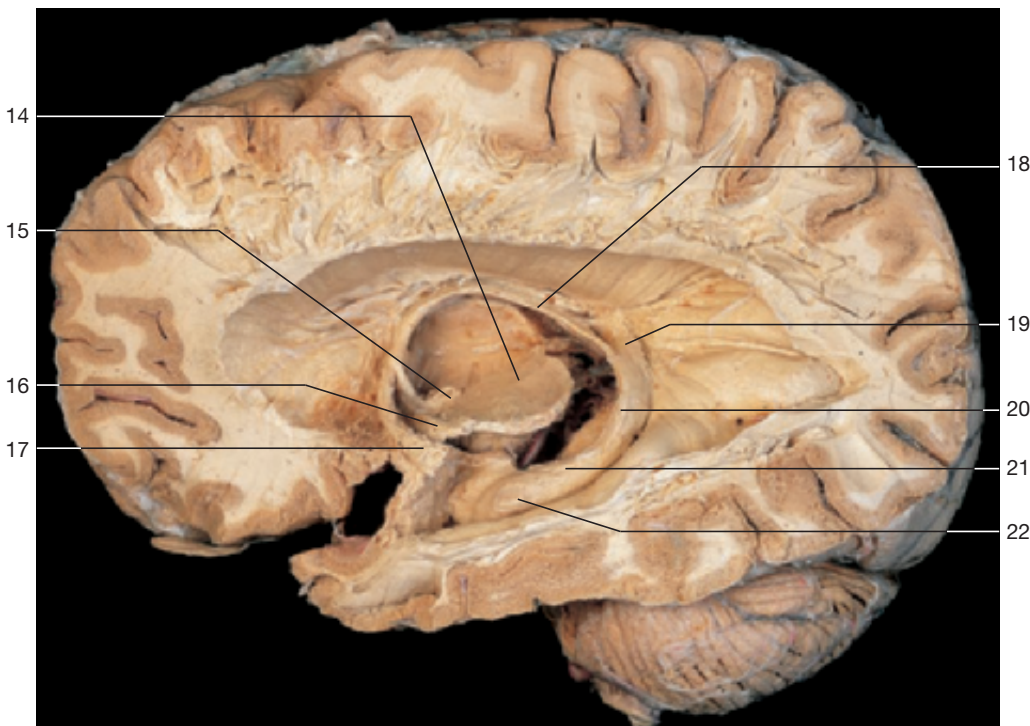


Dorsum of the right foot, deep layer. Extensor digitorum and hallucis brevis muscles have been removed.

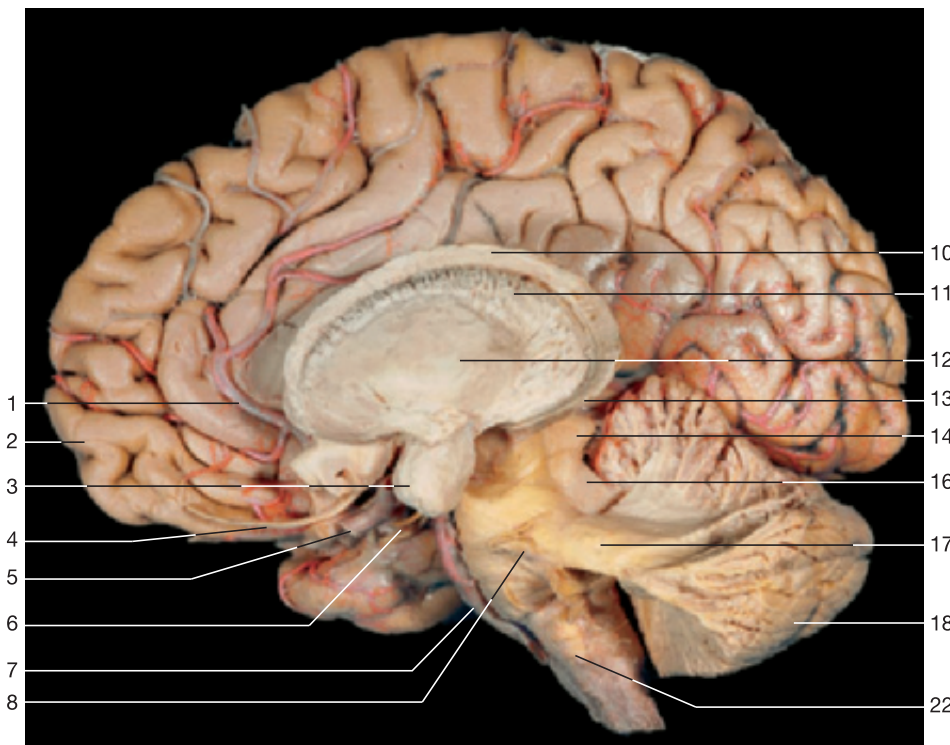


- 1 Corona radiata
- 2 Anterior horn of lateral ventricle
- 3 Head of caudate nucleus
- 4 Putamen
- 5 Anterior commissure
- 6 Olfactory tract
- 7 Amygdala
- 8 Hippocampal digitations
- 9 Internal capsule
- 10 Calcar avis
- 11 Posterior horn of lateral ventricle
- 12 Choroid plexus of lateral ventricle
- 13 Caudal extremity of caudate nucleus
- 14 Pulvinar of thalamus
- 15 Mamillary body
- 16 Optic tract
- 17 Anterior commissure
- 18 Fornix
- 19 Longitudinal stria
- 20 Dentate gyrus
- 21 Hippocampal fimbria
- 22 Pes hippocampi

Dissection of the subcortical nuclei and internal capsule, left hemisphere (lateral aspect). The lateral ventricle has been opened, and the insular gyri and claustrum have been removed, revealing the lentiform nucleus and the internal capsule. Frontal pole to the left.

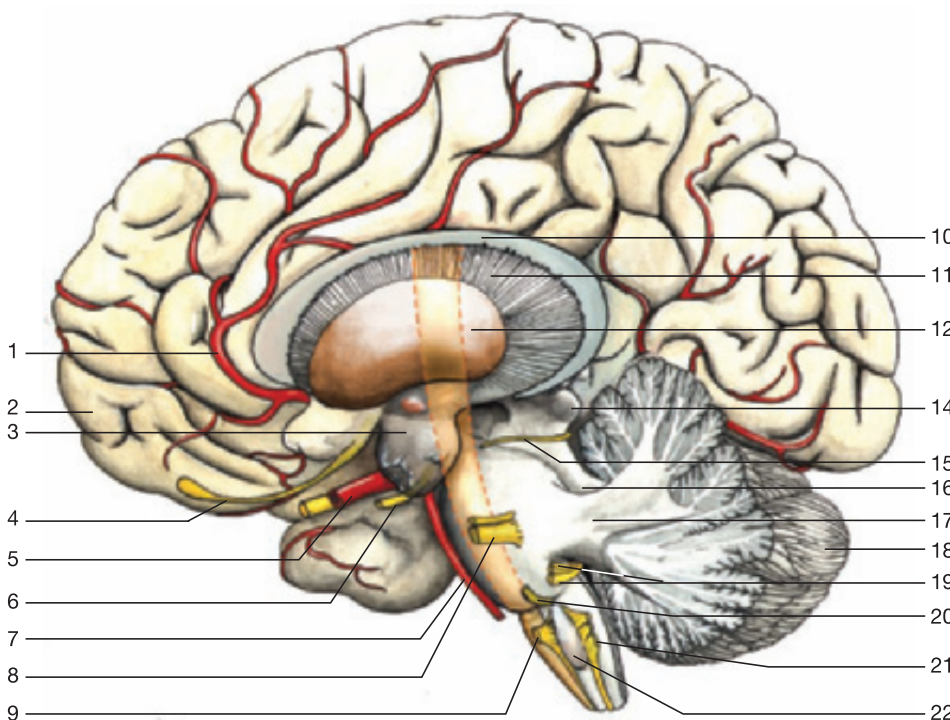


Dissection of the limbic system and fornix, left hemisphere (lateral aspect). Frontal pole to the left.



- 1 Anterior cerebral artery
- 2 Frontal lobe
- 3 Amygdala (amygdaloid body)
- 4 Olfactory tract
- 5 Internal carotid artery
- 6 Oculomotor nerve (n. III)
- 7 Basilar artery
- 8 Trigeminal nerve (n. V)
- 9 Hypoglossal nerve (n. XII)
- 10 Caudate nucleus
- 11 Internal capsule
- 12 Lentiform nucleus
- 13 Caudal extremity of caudate nucleus
- 14 Inferior colliculus of midbrain
- 15 Trochlear nerve (n. IV)
- 16 Superior cerebellar peduncle
- 17 Middle cerebellar peduncle
- 18 Cerebellum
- 19 Facial nerve (n. VII) and vestibulocochlear nerve (n. VIII)
- 20 Abducent nerve (n. VI)
- 21 Glossopharyngeal nerve (n. IX), vagus nerve (n. X), and accessory nerve (n. XI)
- 22 Inferior olive

Dissection of the brain stem and cerebellum (lateral aspect). The connections of the brain stem with the cerebellum are dissected. The amygdala of the left hemisphere is shown. The corpus callosum has been partly removed. Frontal pole to the left.



Schematic drawing of the dissected brain stem and cerebellum shown above (lateral aspect). The course of the pyramidal tracts is indicated in red. Yellow = cranial nerves.

Preface to the Eighth Edition

The knowledge of the structure and topography of the various organs of the human body is a prerequisite not only for the education of medical students but also for everyone involved in diagnostic and therapy of human diseases. This knowledge can optimally be gained by dissection of the human body, with an excellent atlas by one's side. Today there exist a number of good anatomic atlases, but most of them contain mainly schematic drawings, which minimally reflect reality. In contrast, the photographs of the actual anatomic specimens have the advantage of conveying the reality of the object with its proportions and spatial dimensions in a more accurate manner.

On the other hand, schematic drawings help us to better understand the photos. Therefore, in this eighth edition, the number of drawings has greatly been increased and old drawings have been replaced by new ones specifically adapted to their accompanying photos.

The didactic purpose of this atlas is not only to help the student understand the topography of the human body. We also hope to provide a way to systematically learn the anatomical structures and functions. Therefore, the chapters of regional anatomy are consequently placed behind a systematic description of the anatomical structures – e.g., before dissecting an extremity, the

student can study the systematic anatomy of the involved bones, joints, muscles, nerves, and vessels.

The correlations between clinical images like MRI and CT scans can best be learned if sections of scans can be directly compared with cadaveric anatomical sections of the same region. In this edition, a number of MRI scans have been added that have been taken in a plane of the related anatomical section. In addition, functional MRI scans of the heart and the related anatomical preparations are included, hopefully increasing the importance of the atlas for clinical purposes.

While preparing this new edition, the authors were reminded of how precisely, beautifully, and admirably the human body is constructed. If this book helps the student or physician to appreciate the overwhelming beauty of the anatomical architecture of these tissues and organs, then it greatly fulfills its task. Deep interest and admiration of these anatomical structures may create the "love for the human being," which unhesitatingly becomes the inspiration to pursue the vocation of medicine.

Erlangen, Germany; Spring 2015

J. W. Rohen
C. Yokochi
E. Lütjen-Drecoll

The preparations of the anatomical specimens shown in this atlas were time consuming and required profound knowledge. Therefore, all were prepared by anatomists or surgeons. The majority were prepared by the authors and coworkers either in the Department of Anatomy in Erlangen or in the Department of Anatomy, Kanagawa, Dental College in Tokyo. We would like to express our great gratitude to Prof. S. Nagashima, Prof. K. Okamoto, and Dr. M. Takahashi (all Japan) who worked for extended periods in Germany in the Department of Anatomy in Erlangen, and to Dr. K. Schmidt, Dr. G. Lindner-Funk (both Nuremberg), Dr. M. Rexer (Fürth), R.M. Mc Donnell (Dallas, USA), and Mr. J. Bryant (Erlangen) for dissecting specimens with great skill and knowledge.

We are also greatly indebted to Mr. H. Sommer (SOMSO Co., Coburg, Germany) who kindly provided a number of excellent bone specimens.

All the excellent macro photos of specimens newly included in this eighth edition, most notably those of the skeletal system and of the heart, were contributed by our photographer Mr. M. Göbwein, to whom we express our great gratitude.

Most important for this new eighth edition was the work of our artist Mr. J. Pekarsky. He created many new drawings specifi-

cally adapted to the photos in this edition and revised most of the old ones. We express our many thanks to him for his most excellent and time consuming work.

We are greatly indebted to our coworkers from the Department of Radiology, especially Prof. M. Uder and his colleagues (Erlangen) who took the time to perform MRI scans specifically adapted to specimens in our atlas and who added scans to the heart chapter that significantly improved our ability to elucidate the functional aspects of this organ. Also, we extend our thanks to Prof. W. J. Huk and Prof. W. Bautz (both Erlangen), Prof. A. Heuck (Munich), and Dr. Wieners (Berlin) for their excellent MRI and CT scans.

In addition, we express our many thanks to our secretary Mrs. L. Koehler for her untiring and excellent cooperation and to Dr. C. Sims-O'Neil for her careful corrections of the proofs of the new edition.

Finally, we gratefully acknowledge the head of our publisher (Schattauer Verlag, Stuttgart) Mr. D. Bergemann and his coworkers, particularly Mrs. E. Wallstein, who prepared the final layout of the Atlas and worked intensely together with the authors on the new structure of this edition.

Acknowledgments

Preface to the First Edition

Today there exist any number of good anatomic atlases. Consequently, the advent of a new work requires justification. We found three main reasons to undertake the publication of such a book.

First of all, most of the previous atlases contain mainly schematic or semischematic drawings, which often reflect reality only in a limited way; the third dimension, i.e., the spatial effect, is lacking. In contrast, the photo of the actual anatomic specimen has the advantage of conveying the reality of the object with its proportions and spatial dimensions in a more exact and realistic manner than the "idealized," colored "nice" drawings of most previous atlases. Furthermore, the photo of the human specimen corresponds to the student's observations and needs in the dissection courses. Thus he has the advantage of immediate orientation by photographic specimens while working with the cadaver.

Secondly, some of the existing atlases are classified by systemic rather than regional aspects. As a result, the student needs several books each supplying the necessary facts for a certain region of the body. The present atlas, however, tries to portray macroscopic anatomy with regard to the regional and stratigraphic aspects of the object itself as realistically as possible. Hence it is an immediate help during the dissection courses in the study of medical and dental anatomy.

Another intention of the authors was to limit the subject to the essential and to offer it didactically in a way that is self-explanatory. To all regions of the body we added schematic drawings of the main tributaries of nerves and vessels, of the course and mechanism of the muscles, of the nomenclature of the various regions, etc. This will enhance the understanding of the details

seen in the photographs. The complicated architecture of the skull bones, for example, was not presented in a descriptive way, but rather through a series of figures revealing the mosaic of bones by adding one bone to another, so that ultimately the composition of skull bones can be more easily understood.

Finally, the authors also considered the present situation in medical education. On one hand there is a universal lack of cadavers in many departments of anatomy, while on the other hand there has been a considerable increase in the number of students almost everywhere. As a consequence, students do not have access to sufficient illustrative material for their anatomic studies. Of course, photos can never replace the immediate observation, but we think the use of a macroscopic photo instead of a painted, mostly idealized picture is more appropriate and is an improvement in anatomic study over drawings alone.

The majority of the specimens depicted in the atlas were prepared by the authors either in the Dept. of Anatomy in Erlangen, Germany, or in the Dept. of Anatomy, Kanagawa Dental College, Yokosuka, Japan. The specimens of the chapter on the neck and those of the spinal cord demonstrating the dorsal branches of the spinal nerves were prepared by Dr. K. Schmidt with great skill and enthusiasm. The specimens of the ligaments of the vertebral column were prepared by Dr. Th. Mokrusch, and a great number of specimens in the chapter of the upper and lower limb was very carefully prepared by Dr. S. Nagashima, Kurume, Japan.

Once again, our warmest thanks go out to all of our coworkers for their unselfish, devoted and highly qualified work.

Erlangen, Germany; Spring 1983

J. W. Rohen
C. Yokochi